

## Case Report

# Chronic Encapsulated Anterior Abdominal Wall Seroma Post Laparoscopic Intraperitoneal Onlay Mesh Repair for Incisional Hernia: A Case Report

Tan WL (✉), Chan KH, Azman A

Department of Surgery, Hospital Canselor Tuanku Muhriz, Universiti Kebangsaan Malaysia, Jalan Yaacob Latif, Bandar Tun Razak, 56000 Cheras, Kuala Lumpur, Malaysia

### Abstract

Seroma is a collection of serous fluid in a closed space and often occurs and difficult to treat after operation. Here we reported a case of chronic encysted seroma following intraperitoneal onlay mesh repair for incisional hernia of the anterior abdominal wall. A 65-year-old lady with history of midline laparotomy for benign gynaecological disease presented with a reducible incisional hernia over the lower anterior abdominal wall subsequently underwent laparoscopic intraperitoneal onlay mesh repair and had an uneventful post-operative recovery. She presented 4 months later with an irreducible swelling at the hernia repair site. Clinically, there was a 10x10cm swelling lateral to the midline scar. Cough impulse was negative. The clinical presentation was suggestive of a fluid collection and hence an aspiration was performed drawing hemorrhagic fluid consistent with a hematoma. The collection however recurred rapidly within a few weeks. A contrast enhanced computed tomography of the abdomen pelvis was then performed that revealed seroma with no intraperitoneal communication or recurrent hernia. She initially underwent recurrent aspiration which did not resolve the condition and underwent an excision of the anterior abdominal wall encapsulated lesion. Intraoperative findings revealed a superficial 10 x 10 cm encapsulated mass at the anterior abdominal wall which did not communicate with the peritoneal cavity. Histopathological examination revealed a chronic encysted seroma. Chronic seroma can be distressing for patients during postoperative period and may lead to many complications. Aim should be focused on intraoperative techniques to reduce the dead space and tissue dissection. Management for chronic postoperative seroma should be tailored individually.

**Keywords:** Anterior abdominal wall; incisional hernia; IPOM; recurrent seroma; surgical decortication

### Correspondence:

Dr. Tan Wei Lun. Department of Surgery, Hospital Canselor Tuanku Muhriz, Universiti Kebangsaan Malaysia, Jalan Yaacob Latif, Bandar Tun Razak, 56000 Cheras, Kuala Lumpur, Malaysia. Tel: + 6017-9414589 E-mail: wei89lun@gmail.com

Date of submission: 10 Dec, 2023

Date of acceptance: 19 Jan, 2024

### Introduction

Seroma is an abnormal accumulation of serous fluid in a dead space containing lymphatic fluid and plasma (1,2). Seroma often occurs post-surgery, especially in hernia repair surgery, breast surgery, abdominoplasty and plastic surgery. Tissue dissection and dead spaces in the wound are contributing factors which lead to variable seroma collection sizes (3). This may be due to a local inflammatory reaction to the traction injury during tissue handling and dissection and the introduction of foreign materials, such as sutures, into the body (4). Seroma formation after laparoscopic

inguinal hernia repair often occurs, with incidences ranging from 1.9-22.9% in literature (5,6,7). Herein, we reported a chronic encysted seroma following intraperitoneal onlay mesh repair for the anterior abdominal wall incisional hernia.

### Case Report

A 65-year-old woman with a history of midline laparotomy for benign gynaecological disease presented to our centre with a reducible incisional hernia over the lower anterior abdominal wall. Her past medical history included dyslipidemia, type 2

diabetes mellitus, and hypertension. She underwent an elective laparoscopic intraperitoneal on-lay mesh repair and had an uneventful post-operative recovery.

However, she presented back to our centre four months later with an irreducible swelling at the hernia repair site. On examination, there was a 10x10 cm swelling slightly lateral to the midline scar, which was well-defined, non-tender and firm in consistency. The cough impulse was negative. The clinical picture suggested a post-operative fluid collection, and hence, aspiration was performed, drawing serous fluid consistent with a seroma. The collection, however, recurred rapidly within a few weeks, with the patient presenting a painless swelling over the surgical site in a similar fashion.

A contrast-enhanced computed tomography of the abdomen pelvis was then performed and revealed a subcutaneous cystic lesion consistent with seroma, with no intraperitoneal communication or recurrent hernia (Fig. 1). She was initially treated with bedside aspiration. However, the seroma was recurrent.

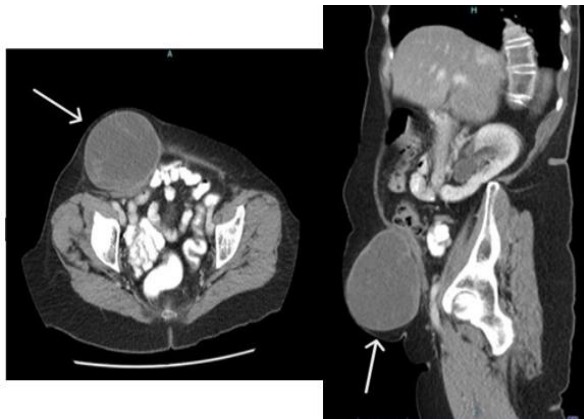


FIGURE 1: A contrasted enhanced CT of the abdomen and pelvis showed a large subcutaneous cystic lesion at the anterior abdominal wall

She then underwent an excision of the anterior abdominal wall encapsulated lesion. Intraoperative findings revealed a superficial 10x10 cm encapsulated mass at the anterior abdominal wall, which did not communicate with the peritoneal cavity (Fig. 2). The mass was cystic with brownish fluid within it, consistent with a seroma with hemorrhagic transformation (Fig. 3). Histopathological examination revealed a chronic encysted seroma. She recovered well postoperatively. Follow-up at one-year period showed no more recurrent seroma.

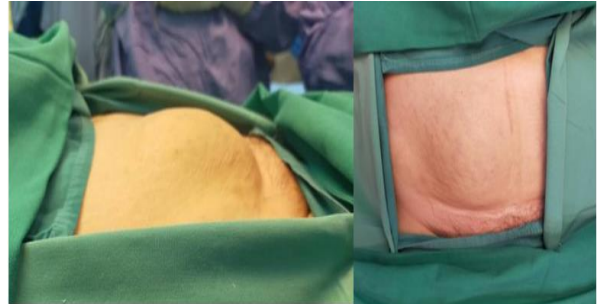


FIGURE 2: Intraoperative showed a large mass protruding from the anterior abdominal wall

## Discussion

Post-operative seroma is a common complication after any surgical procedure. Recurrent and chronic seroma may be troublesome for patients and may lead to other complications. Multiple predisposing factors can contribute to seroma formation, including obesity, large surgical dead space and diabetes mellitus. There is no definitive management of chronic and recurrent seroma in the literature thus far, as most studies focus on preventing seroma formation (8). Surgical principles, including obliterating the dead space and reducing the shearing force, may help to reduce the amount of seroma but do not entirely prevent it.

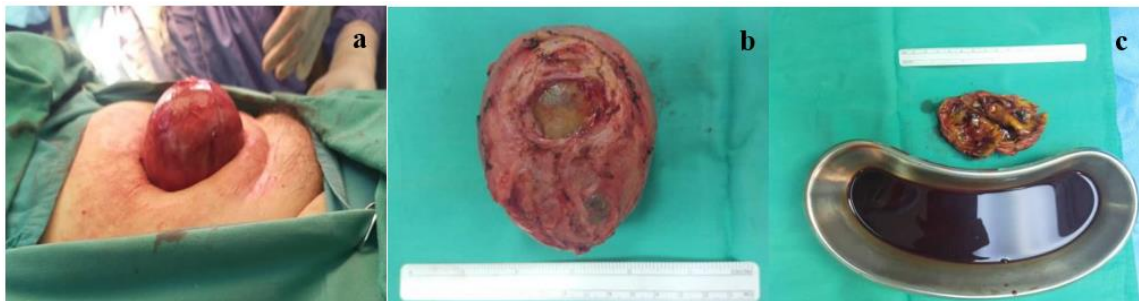

FIGURE 3: (a) Intraoperative showed a large encapsulated seroma after dissection; (b & c) Postoperative specimen showed the encapsulated seroma with its content

Aspiration or drainage is one of the main techniques to treat seroma. However, most of the chronic seromas tend to recur after multiple aspiration. This is because seroma walls are lined by a pseudo capsule and fibrous tissue (9). Additional procedures like percutaneous drainage and chemical or surgical decortication are needed to treat chronic seroma (10,11). Chemical decortication using sclerosing agents, i.e. povidone iodine, fibrin glue, doxycycline, tetracycline, alcohol, erythromycin and talc, can be used. These various methods have shown promising results in treating chronic seroma with minimal complications; however, only a few cases were reported in the literature, and study results were inconsistent (12,13). According to Lopez et al., multicentric prospective studies in Spain using talc to treat chronic seroma have been ineffective, with a high recurrent rate (10). In our case, chemical decortication was not offered, as we believed the failure rate would be increased due to the seroma's large size.

In the current literature, only a handful of case reports have shown that surgical excision of chronic seroma is the most effective treatment. (14,15). However, no definitive studies have demonstrated the operative indications, timing of surgical intervention and outcomes after surgery for chronic seroma. Most surgical techniques apply basic surgical principles such as complete excision en bloc together with the capsule of seroma to obliterate the dead space. After clinical examination and radiological imaging, such as a computed tomography (CT) scan to delineate the extension of the seroma, we opted for surgical excision as we believed it would have been the best modality to treat the seroma.

### Conclusion

Chronic seroma can cause anxiety and chronic pain in patients in the postoperative period. This can lead to many complications, such as wound infection, wound dehiscence, and psychological distress to patients and their family members. There is no single method effective in treating chronic postoperative seroma. The aim should be focused on prevention, such as intraoperative techniques to reduce the dead space and minimise unnecessary tissue dissection. Management for chronic postoperative seroma should be tailored individually.

### References

1. Agrawal A, Ayantunde AA, Cheung KL. Concepts of seroma formation and prevention in breast cancer surgery. *ANZ J Surg* 2006; 76(12): 1088-95.
2. Kuroi K, Shimosuma K, Taguchi T, Imai H, Yamashiro H, Ohsumi S, Saito S. Effect of mechanical closure of dead space on seroma formation after breast surgery. *Breast Cancer* 2006; 13(3): 260-5.
3. Lau H, Lee F Seroma following endoscopic extraperitoneal inguinal hernioplasty. *Surg Endosc* 2003; 17(11): 1773-7.
4. Robert B, Jack A, Maurice EA, Jean BF, Edward HP. *Abdominal wall hernias principles and management*. New York: Springer Publishing 2001; 753-6.
5. Kapiris SA, Brough WA, Royston CM, O'Boyle C, Sedman PC. Laparoscopic transabdominal preperitoneal (TAPP) hernia repair: A 7-year two-center experience in 3017 patients. *Surg Endosc* 2001; 15(9): 972-5.
6. Fitzgibbons RJ Jr, Camps J, Cornet DA, et al. Laparoscopic inguinal herniorrhaphy: Results of a multicenter trial. *Ann Surg* 1995; 221(1): 3-13.
7. Leibl BJ, Schmedt CG, Kraft K, Ulrich M, Bittner R. Scrotal hernias: A contraindication for an endoscopic procedure? Results of a single institution experience in transabdominal preperitoneal repair. *Surg Endosc* 2000; 14(3): 289-92.
8. Morris BE, Thornburg DA, Teven CM, Kruger EA. Surgical management of chronic encapsulated abdominal wall seroma 8 years after abdominoplasty. *Plast Reconstr Surg Glob Open* 2021; 9(7): e3697.
9. Chittawadagi B, Senthilnathan P, Palanivelu C. Chronic encysted giant seroma post-ventral hernia repair masquerading as peritoneal cyst and its laparo-seroscopic management: A case report and literature review. *J Minim Access Surg* 2021; 17(2): 241-4.
10. Lopez-Monclus J, Artes M, Gonzalez J, et al. Failure of talc seromadesis for the treatment of subcutaneous chronic seromas after incisional hernia surgery. *Scand J Surg* 2019; 110(1): 105-9.
11. Mayagoitia JC, Almaraz A, Díaz C. Two cases of cystic seroma following mesh

- incisional hernia repair. *Hernia*. 2006; 10(1): 83-6.
12. Sood A, Kotamarti VS, Therattil PJ, Lee ES. Sclerotherapy for the management of seromas: A systematic review. *Eplasty* 2017; 17: e25.
  13. Al Daoud F, Thayer A, Sachwani Daswani G, Maraqa T, Perinjelil V, et al. Management of chronic abdominal wall seroma with doxycycline sclerotherapy using a negative pressure wound therapy system KCI-V.A.C.Ult<sup>TM</sup> - A case report. *Int J Surg Case Rep* 2018; 51: 25-8.
  14. Goldman A, Wollina U, França K, Tchernev G, Lotti T. Chronic encapsulated seroma persisting for three years after abdominoplasty and a successful surgical solution. *Open Access Maced J Med Sci* 2018; 6(1): 82-4.
  15. Caulfield RH, Maleki-Tabrizi A, Khan F, Ramakrishnan V. A large encapsulated seroma presenting as a mass 5 years post paraumbilical hernia repair. *J Plast Reconstr Aesthet Surg*. 2009; 62(1): 105-7.