

## Case Report

# Ocular Leptospirosis Presenting as Neuroretinitis in Patients without Systemic Symptoms

Azal AB<sup>1</sup>, Mohammad Razali A<sup>1</sup>, Raja Othman RNF<sup>2</sup>, Ahmad Tarmizi A<sup>2</sup>, Naffi AA, Md Din N (✉)

<sup>1</sup>Department of Ophthalmology, Faculty of Medicine, Universiti Kebangsaan Malaysia, Jalan Yaacob Latif, Bandar Tun Razak, 56000 Kuala Lumpur, Malaysia

<sup>2</sup>Department of Ophthalmology, Kuala Lumpur Hospital, Jalan Pahang 50586, Kuala Lumpur, Malaysia

### Abstract

Neuroretinitis is an atypical presentation of ocular leptospirosis. Patients present with neuroretinitis as the only sign of leptospirosis which poses a diagnostic challenge. We reported two cases of ocular leptospirosis with neuroretinitis presentation in healthy individuals. Both patients presented swollen discs, macula star and retinal vasculitis. None of the patients had systemic symptoms of leptospirosis before the ocular complaint. Both patients were treated with oral doxycycline for four weeks and recovered well.

**Keywords:** Doxycycline; leptospirosis; macular star; neuroretinitis; retinal vasculitis

### Correspondence:

Norshamsiah Md Din. Department of Ophthalmology, Faculty of Medicine, Universiti Kebangsaan Malaysia, Jalan Yaacob Latif, Bandar Tun Razak, 56000 Kuala Lumpur, Malaysia. Tel: +603-91455981/5982 E-mail: nsd@ppukm.ukm.edu.my

### Introduction

Leptospirosis is a common disease in tropical countries caused by water-borne spirochete of the genus *Leptospira*. It has a wide range of clinical presentations, often is mistaken for other diseases. The classical presentation is an acute biphasic febrile illness. An ocular manifestation of leptospirosis remains underdiagnosed mainly because of a prolonged symptom-free period separating the systemic symptoms from ocular manifestation (1). Common ocular features include conjunctival chemosis, subconjunctival haemorrhage, keratitis, uveitis, cataract, vitritis and hypopyon. Neuroretinitis is an atypical form of ocular leptospirosis (1). Despite prior diagnosis dilemmas, we presented two patients with good visual outcomes after prompt definitive therapy.

### Case Report

### Case 1

A 46-year-old woman with uncontrolled diabetes mellitus presented with painless progressive left eye (LE) blurring of vision for one week. There was no history of recent travelling, jungle trekking or river swimming. She had a history of cat scratches a few weeks earlier but no flu-like symptoms. Ocular examination revealed visual acuity 6/18 in the right eye (RE) and 4/60 in the LE with left positive relative afferent pupillary defect (RAPD). Anterior segment examinations were normal. Fundus examination revealed bilateral optic disc swelling with disc haemorrhage, which was more seen in the LE (Fig. 1A), dot-blot haemorrhage and cotton wool spots around the optic disc in RE and incomplete macula star with vasculitis inferonasal in LE. There was no retinitis or choroiditis in both eyes. Systemic examinations were normal. The optical coherence tomography of the macula showed hard exudates and subfoveal with intraretinal fluid in the left eye (Fig. 2A).

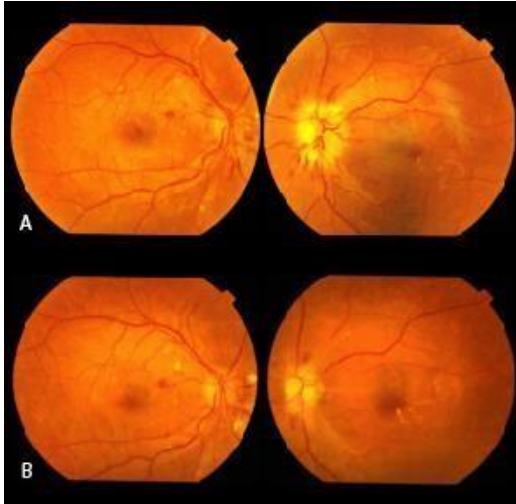


FIGURE 1: (A) Fundus photos at presentation showed bilateral disc swelling and haemorrhages. Left eye showed incomplete macula star and vasculitis inferonasally; (B) Fundus examination five weeks post-treatment showed resolution of optic disc oedema and partial resolution of the macula star

Blood investigations showed mild leucocytosis with elevated ESR (42 mm/hr). Mantoux test and chest x-ray were negative. Venereal Disease Research Laboratory (VDRL) testing for *Treponema Pallidum*, autoimmune screening, serologic tests for HIV, Hepatitis B and C, and toxoplasmosis were all negative.

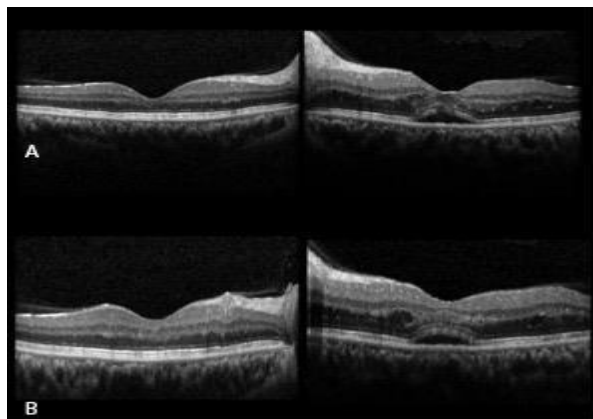


FIGURE 2: (A) Image from the Optical Coherence Tomography (OCT) of the macula at presentation showed hard exudates, subfoveal and intraretinal fluid in the left eye; (B) OCT images after treatment showed partial resolution of macula oedema

Based on a strong clinical suspicion, the patient was empirically treated with intravenous ceftazidime 1g twice daily for one week, followed by oral ciprofloxacin 500 mg twice daily while waiting for other infectious serological tests. Oral prednisolone was started a week later to reduce the disc swelling. The serological report came back as *Leptospira* IgM positive. The *Bartonella* serology was negative. The patient was then started on oral Doxycyclin 100 mg twice daily for two weeks. After five weeks, the patient's vision improved to RE 6/9 and LE 6/12 with a resolution of disc oedema and macula star (Fig. 1B). The optical coherence tomography showed improvement in the intraretinal fluid (Fig. 2B).

## Case 2

A 39-year-old woman with underlying hypertension presented with sudden onset of LE central scotoma for six days and pain in eye movement for two days. Otherwise, there was no preceding flu-like illness or history of recent jungle trekking or swimming in the river. She had pet cats at home but denies any cat scratches.

Ocular examination revealed visual acuity 6/9 in the RE and 6/60 in the LE with no RAPD. Anterior segment examination was normal. Fundus examination revealed vascular sheathing nasally and multiple cotton wool spots in RE. The left optic disc was swollen and hyperaemic with macula star and numerous cotton wool spots (Fig. 3A). The veins were dilated and tortuous. There was no retinitis or choroiditis.

Her blood pressure at presentation was 155/94 mmHg. Other systemic examinations were unremarkable. She was admitted and initially treated for hypertensive retinopathy grades 3 to 4.

Blood investigations showed high C-reactive protein (0.85) and ESR (93 mm/hr). Full blood count was normal. Mantoux test and chest x-ray were unremarkable. VDRL test was negative. Fundus fluorescein angiography showed a bilateral hot disc (Fig. 4) but no evidence of vasculitis.

She was referred to the rheumatology team to rule out connective tissue disease. She was suspected of having Takayasu arteritis because of her weak left radial and brachial pulse and high ESR level. However, she did not fulfil the diagnostic criteria of Takayasu arteritis as her CT brain angiogram showed no significant abnormality, and the carotid Doppler ultrasound was normal.

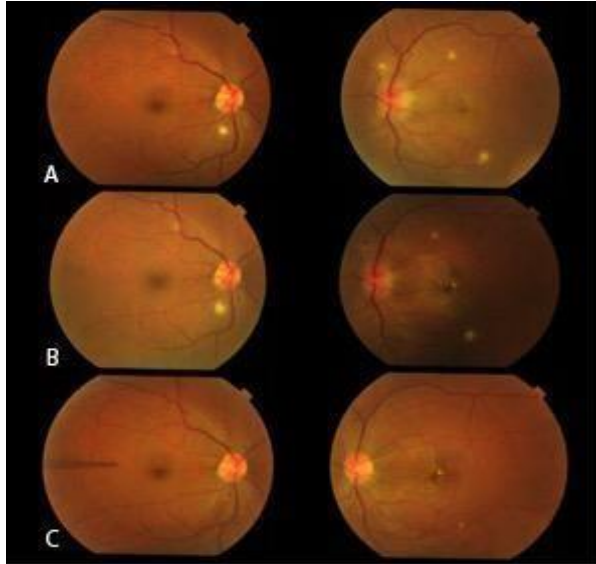


FIGURE 3: (A) Fundus photos on the initial presentation showed the bilateral cotton wool spot. There was optic disc swelling with macula star in the LE; (B) One week after treatment with oral doxycycline, showing improvement of optic disc swelling with prominent macula star; (C) Fundus photo showed complete resolution of optic disc swelling

She was referred to the rheumatology team to rule out connective tissue disease. She was suspected of having Takayasu arteritis because of her weak left radial and brachial pulse and high ESR level. However, she did not fulfil the diagnostic criteria of Takayasu arteritis as her CT brain angiogram showed no significant abnormality, and the carotid Doppler ultrasound was normal.

She was empirically treated for atypical infection and started on oral Doxycycline 100 mg twice daily. A week after treatment, the retinitis showed signs of resolution with improved vision to 6/24 (Fig. 3B). Oral prednisolone (0.5 mg/kg/day) was started after completing the antibiotics. Serology infective screening results showed double serology positive as *Leptospira* IgM positive and *Bartonella henselae* positive (IgM 1:24 and IgG 1:128). After four weeks of oral Doxycycline (Fig. 3C), her LE vision improved to 6/9 with a resolution of optic disc swelling and macula star.

## Discussion

Leptospirosis is a systemic illness caused by the spirochete *Leptospira*. It is an infectious zoonotic disease and endemic in tropical and subtropical

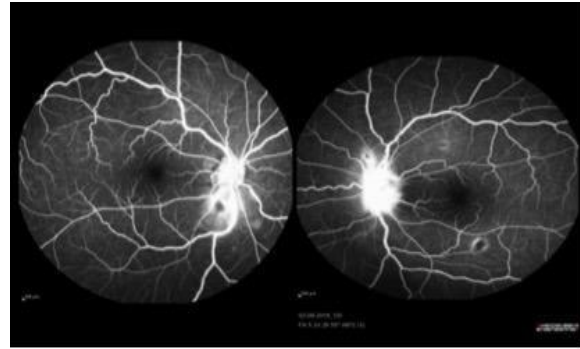


FIGURE 4: Fundus fluorescein angiogram showed bilateral hot disc and cotton wool spots

regions, typically in areas with heavy rainfall and flooding (1).

The reservoir and carrier hosts are rats, cattle, dogs, foxes and rabbits. These animals harbour many *Leptospira* in their urine and contaminate the environment, e.g. water and soil. The bacteria can enter the bloodstream through intact or abraded skin and mucus membrane/ conjunctiva. Infection can also spread through ingestion of contaminated water (1,2).

It is called “the great mimicker” because of its vast clinical manifestation, ranging from as mild as a flu-like symptom to potentially fatal conditions such as haemorrhagic fever and multiorgan failure. *Leptospira* invades small blood vessels and causes endothelial cell damage. The clinical manifestation depends on the organ involved. In the first week of initial bacteremia, *Leptospira* are eliminated by the immune system, except from immunologically privileged organs such as the brain and eyes. Late complications such as aseptic meningitis and uveitis occur during the immune phase of the disease, in which the bacteria are cleared from the system once an antibody response occurs (1,2).

The most common ocular feature of leptospirosis is conjunctival chemosis, occurs in the acute phase of the disease (3). Uveitis is the most typical late complication (2-10% of ocular leptospirosis), which occurs between 2 months to 2 years after the latent period (4) Other features include keratitis, scleral icterus, iritis and iridocyclitis in the anterior segment. Among the posterior segment manifestations are vitritis, pars planitis, peri phlebitis, choroiditis, papillitis, macular oedema, retinal haemorrhages, retinal exudates, and arteritis (1,5,6).

Both of our patients presented with neuroretinitis, which is an uncommon manifestation of leptospirosis. Neither patient had any systemic symptoms of leptospirosis, such as fever, conjunctival injection, jaundice and hepatosplenomegaly before the ocular complaint, and neither had they had any positive history of exposure to a contaminated environment, making the diagnosis a challenge.

Our first patient was initially treated as cat scratch disease because of a positive history of cat scratch. She responded well to the initial treatment with intravenous ceftazidime, which is also the treatment for leptospirosis.

In our second patient, the clinical features initially appeared like grade 3 or 4 hypertensive retinopathy, with bilateral disc swelling and some exudates at the macula. We attributed the optic disc swelling to this hypertensive retinopathy. However, because the macular star appeared more prominent, and the disc swelling was unilateral, neuroretinitis was considered.

The first reported case of neuroretinitis secondary to leptospirosis was in 1984 by Dreyer et al. (1984)(7), and subsequently, other authors described similar cases (1,3,8). While leptospirosis is a common disease in our population, neither of our patients had systemic symptoms of leptospirosis before the eye symptoms.

Diagnosis of neuroretinitis in leptospirosis is based on the exposure history of contaminated environment, ocular findings and positive serology of leptospira antibody. Detection of IgM antibodies by enzyme-linked immunoassays is highly sensitive and is a rapid method for leptospira antibody detection. The microscopic agglutination test (MAT) is the gold standard to diagnose leptospira. This test can detect the infecting serovar and determine the antibody titres. Leptospira can also be cultured from blood and cerebrospinal fluid in the acute phase of illness. Diagnosis in our cases was confirmed by a positive antibody serology (1,2). In our second case, Leptospira and Bartonella IgM serologies were positive as opposed to the first case.

Antibiotic therapy such as doxycycline (2 mg/kg up to 100 mg 12-hourly for 5-7 days), tetracycline, ampicillin or amoxicillin; third-generation cephalosporins, such as ceftriaxone and cefotaxime; and quinolone are effective to treat leptospirosis. Steroids do not influence the final visual outcome, but they are preferred to reduce the inflammatory response and treat the underlying immune-mediated outcome (1,6).

## Conclusion

Ocular manifestation of leptospirosis may present in patients with subclinical systemic symptoms. Leptospirosis should be suspected in cases of neuroretinitis. Awareness of this condition is paramount to establish a definitive therapy for this treatable illness.

## References

1. Rathinam SR. Ocular manifestations of leptospirosis. *J Postgrad Med* 2005; 51(3): 189-94.
2. Verma A, Stevenson B. Leptospiral uveitis – There is more to it than meets the eye! *Zoonoses Public Health* 2012; 59(s2): 132-41.
3. Martins MG, Matos KTF, da Silva MV, de Abreu MT. Ocular manifestations in the acute phase of leptospirosis. *Ocul Immunol Inflamm* 1998; 6(2): 75-9.
4. Rathinam SR, Rathnam S, Selvaraj S, Dean D, Nozik RA, Namperumalsamy P. Uveitis associated with an epidemic outbreak of leptospirosis. *Am J Ophthalmol* 1997; 124(1): 71-9.
5. Asensio-Sánchez VM, Haro-Álvarez B, Herreras J, Martín-Prieto A. Unusual ocular clinical manifestation of leptospirosis. *Arch Soc Esp Ophthalmol* 2018; 93(7): 342-6.
6. Rathinam SR. Ocular leptospirosis. *Curr Opin Ophthalmol*. 2002; 13(6): 381-6.
7. Dreyer RF, Hopen G, Gass JM, Smith J. Leber's idiopathic stellate neuroretinitis. *Arch Ophthalmol* 1984; 102(8): 1140-5.
8. Ghosh S, Das R, Saha M, Das D. Neuroretinitis as an unusual manifestation of leptospirosis: A case report. *J Clin Exp Ophthalmol*. 2011; 2(1): 1-2.