

Case Report

Presumed Tuberculous Keratopathy: A Rare Presentation of “Serpiginous-Like” Keratic Precipitates in a Unilateral Anterior Uveitis Case

Gaayathri N, Wong HS, Muhaya M, Hazlita MI (✉)

¹Department of Ophthalmology, Faculty of Medicine, Universiti Kebangsaan Malaysia Medical Centre, Jalan Yaacob Latif, Bandar Tun Razak, 56000 Cheras, Kuala Lumpur, Malaysia.

²Department of Ophthalmology, Kuala Lumpur Hospital, Jalan Pahang, 50586, Wilayah Persekutuan Kuala Lumpur, Malaysia.

Abstract

A 43-year-old lady with no underlying medical illness was referred for chronic recurrent unilateral anterior uveitis. She had no previous ocular trauma or surgical intervention to the eye. Upon presentation, she was found to have unilateral anterior uveitis with a very unusual “serpiginous-like” pattern of keratic precipitate. Initial investigations revealed no infective cause and patient was commenced on topical and oral steroids. Unfortunately, her ocular symptoms worsened and developed steroid induced glaucoma. A repeat infective screening revealed positive results for tuberculosis. Patient has since responded very well to treatment with antitubercular agents with complete resolution of the inflammation and good visual recovery. In this case report, we wish to emphasize that ocular tuberculosis presentation is highly variable and in such cases its best to employ a high index of suspicion to initiate the right treatment timely. An infective etiology should promptly be suspected in patients who are not showing response to topical or systemic steroids. Even in an immunosuppressed state, ocular tuberculosis may remain unilateral throughout the course of the disease, as seen in the patient. Injudicious use of steroid can make a simple anterior granulomatous uveitis progress to florid granulomatous uveitis with confluent keratic precipitates.

Keywords: Anterior uveitis, antitubercular agents, cornea (keratic) precipitates, topical corticosteroids, Tuberculin test

Correspondence:

Hazlita Mohd Isa, Department of Ophthalmology, Faculty of Medicine, Universiti Kebangsaan Malaysia Medical Centre, Jalan Yaacob Latif, Bandar Tun Razak, 56000 Cheras, Kuala Lumpur, Malaysia. Tel: +603-9145 5981 Fax: +603-9145 6673 Email: drhdm1@yahoo.co.uk

Date of submission: 11 May, 2016

Date of acceptance: 5 Aug, 2016

Introduction

Ocular tuberculosis has always been a diagnostic challenge to clinicians as its presentation is highly variable. Certain classical presentations have been identified including phlyctenulosis and broad base posterior synechia anteriorly and choroidal tubercles posteriorly (1); that help to narrow down the possibilities. There has been one report of tuberculous keratitis in a post corneal transplant eye; however that can be easily attributed to the immunocompromised state of the eye (2). Apart from that the anterior part of the eye may developed a tuberculous abscess mimicking a chalazion, necrotizingscleritis and

interstitial keratitis (3). However, never has a peculiar pattern of keratic precipitates been documented nor attributed to tuberculosis previously. By reporting this case, we would like to stress on the endless possible ocular tuberculosis presentation that can aid clinicians to start therapy early and save the patient from poor vision and steroid related complications.

Case Report

A 43-year-old lady was referred from a Peripheral Eye Centre for recurrent left eye redness for the past 10 months. There was associated reduced vision and photophobia, but no history of discharge, pain, nausea

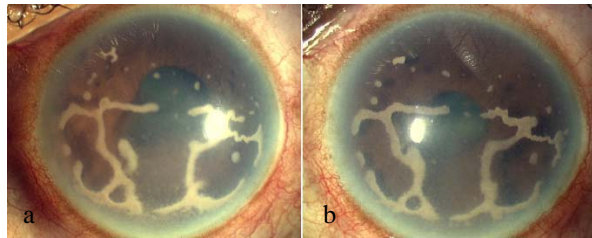


Figure 1: a) Left eye on presentation with mutton fat keratic precipitates forming an unusual “serpent-like” pattern, b) Worsening of the keratic precipitates after commencing oral steroids and azathioprine

or vomiting. She denied history of trauma to the left eye; as well as history of prolonged fever, weight loss or appetite and other constitutional symptoms.

She was diagnosed to have a left granulomatous anterior uveitis at her referring hospital and was treated with intensive topical steroids and an anti-inflammatory dose of oral prednisolone. She initially showed some response to the treatment but had several episodes of recurrences thereafter, which became harder to control with medications. She subsequently developed left steroid induced glaucoma which was successfully controlled with topical Timolol alone. Her problem in the left eye however persisted, despite being on topical and oral steroids, and her vision in that eye continued to deteriorate. It was then she was referred to our centre for further management of her eye problem.

The patient was otherwise healthy. She is a home maker and did not have a family history of similar ocular presentation or complaints.

Ocular examination on presentation revealed a right visual acuity of 6/6 and a left visual acuity of counting fingers at 2 feet. Anterior segment examination of the left eye revealed a circumcorneal conjunctival injection. There was no evidence of discharge or chemosis. The left cornea was hazy. Dense, confluent mutton fat keratic precipitates which formed an unusual “serpentine-like” pattern was seen on the corneal endothelium of the left eye. The anterior chamber was noted to be deep and had occasional cells. There was also evidence of a posterior synechiae from 4 to 7 o'clock (Fig. 1a). The fundus examination was normal with no evidence of vitritis or choroiditis. Examination of the fellow eye was unremarkable and a complete systemic examination performed on her revealed no abnormalities.

Her full blood count and picture revealed a slightly raised total white count ($11.1 \times 10^9/L$) which was predominantly an elevation of neutrophil count. She had also come with the results of some blood investigation that were done just prior to her referral. The ESR report was normal 27mm/hour. The Mantoux

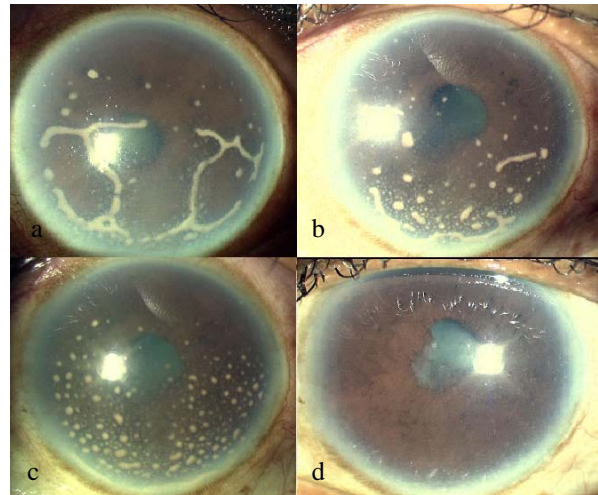


Figure 2: a) Keratic precipitates improving 2 days after starting antitubercular agents, b) At 1 week follow up, c) At 1 month follow up, d) At 3 months follow up.

that was performed at the referral centre was non-reactive (3mm) to indicate a tuberculosis infection. The rapid plasma regain (RPR/VDRL) was also non-reactive which made syphilis infection unlikely. Twenty four hour urine calcium was also normal (7.4mmol/24hours) which helps to exclude the diagnosis of sarcoidosis.

The chest radiograph showed no adenopathy or parenchymal changes to suggest sarcoidosis. There were no focal lung lesions suggestive of tuberculosis.

Based on the investigations, the patient was provisionally diagnosed as a unilateral idiopathic severe anterior granulomatous uveitis and was commenced on oral prednisolone 60mg, oral azathioprine 50mg three times daily and topical betamethasone every two hourly in the left eye. Unfortunately, after 4 days being on treatment, patient showed no signs of improvement in the left eye. Instead, the mutton fat keratic precipitates were noted to have worsened slightly (Fig. 1b).

In view of this, an infective cause was highly suspected and oral azathioprine was stopped. The infective screen and ESR were repeated, which revealed a positive Mantoux of 17mm together with a raised ESR of 117mm/hour. A diagnosis of left chronic granulomatous uveitis secondary to tuberculosis was made and patient was commenced on antitubercular agents along with the topical medications. She was planned for a vitreous tap for tuberculosis PCR (polymerase chain reaction) and also a Quantiferon Gold test, however we could not proceed with these confirmatory tests due to the patient's financial constraints. The patient was also

referred to our respiratory team to rule out pulmonary and extrapulmonary tuberculosis. Two days after commencement of antitubercular agents, patient showed marked improvement in her left eye. Her vision improved from counting fingers at 6 feet to 6/18. The conjunctival injection also reduced. The mutton fat keratic precipitates became smaller and started to break down (Fig. 2a). The oral prednisolone and topical betamethasone were tapered gradually.

After 3 months on antitubercular agents, her left visual acuity improved to 6/9. Her left eye was noted to be white and the keratic precipitates was found to have nearly disappeared (Fig. 2b, 2c and 2d). The antitubercular agents were continued for six months, as planned by the respiratory physicians. Oral prednisolone was maintained at 5mg daily, topical betamethasone was reduced to four times a day and both were stopped after three months.

Our patient remained symptom free at her 6 months and 1 year follow-up. She has had no recurrences since then.

Discussion

Clinical manifestation of ocular tuberculosis may appear in many different forms. This may be primary or secondary in nature which results from either contagious spread from adjacent structure or haematogenous spread. The most common ocular tuberculosis presentations are choroiditis, anterior uveitis, choroid tubercles, retina vasculitis, vascular occlusion, dense vitritis and papillitis (4,5).

Patients with ocular tuberculosis mostly have no systemic signs of tuberculosis, rendering definitive diagnosis difficult (6). Furthermore, 50% of these patients will have normal chest radiograph. In ocular tuberculosis, the diagnosis can be made by finding acid-fast bacilli microorganisms, during microscopic examination of diagnostic specimen such as vitreous or aqueous aspiration. As shown in this case, the Mantoux test is of limited value, because of its low sensitivity and specificity.

Recent advances in diagnostic technique include amplification of DNA polymerase chain reaction (PCR) which has high sensitivity and specificity (7). It is useful for diagnosis of primary ocular tuberculosis because only small sample is needed and viable cells are not required.

Therefore diagnosis of ocular tuberculosis is often presumptive based on indirect evidence, such as intractable uveitis unresponsive to steroid therapy and

negative findings for other causes of uveitis (8). Abrams and Schlaegel from the USA reported that tuberculosis should be suspected in patients presenting with either granulomatous or non-granulomatous uveal lesions, especially in cases of chronic iridocyclitis (9).

In a large study conducted in 2004 by Gupta in North India, a diagnosis of intraocular tuberculosis was made when a patient fulfilled certain criteria, some of which are presence of granulomatous anterior uveitis, Mantoux of approximately 20mm and a response to antitubercular agents (10). Based on this criteria, out of 235 patients with anterior uveitis due to a specific cause, 48 patients were diagnosed with tuberculosis (10). These criteria aids in diagnosis when clinical signs are atypical and laboratory results are ambiguous or unavailable (10). Tuberculosis also constituted the most common infective cause of anterior uveitis in these patients and an almost similar incidence was reported in a collateral study in Italy (10).

In this case, she presented with an unusual form of severe granulomatous anterior uveitis with dense, atypical confluent mutton fat keratic precipitates and posterior synechiae. Her previous history of being unresponsive to systemic and oral steroid should have raised the suspicion that her condition was infective in nature. However, with an initial negative Mantoux test and normal ESR, a diagnosis of tuberculosis was not convincing.

Abrams and Schlaegel further suggested that, because of the difficulty in diagnosing ocular tuberculosis clinically and obtaining microbiologic evidence, a diagnosis of presumed intraocular tuberculosis can be made on the basis of a good response to a clinical trial of isoniazide. As proven in this case, she showed marked improvement in her condition after a clinical trial of antitubercular agents that consists of Isoniazid thus assisting the diagnosis of ocular tuberculosis.

It is highly likely that the initial negative Mantoux test portrayed in this patient is probably due to prolonged steroid intake prior to presentation, leading to suppression of her immunity and not enabling her to mount a reaction to the Mantoux test. Interestingly however, despite this suppressed immunity, her ocular tuberculosis involvement remained unilateral and she portrayed no other systemic involvement.

The role of keratic precipitates in this case should also be highlighted. Not only can keratic precipitates manifest in different ways but it have played a key role as an indicator of the disease process and progression. A study evaluating keratic precipitates in 33 individuals with either infective or non-infective

uveitis via in vivo confocal microscopy (IVCM) revealed an interesting observation (11). Patients with keratic precipitates due to an infective cause had a infiltrating and dendritic pattern, whereas those due to a non-infective cause had a more smooth and globular pattern (11). As the results in this study were very consistent, evaluating keratic precipitates via this method may help diagnose elusive uveitis cases in the future.

In conclusion, ocular tuberculosis has a very protean presentation and may not always present in the typical presentations mentioned earlier. A sound knowledge on the possible clinical presentations of this condition may save a patient's vision as this condition is treatable.

Conclusion

Orbital SFT is rare but should be considered as one of the different diagnosis when dealing with an orbital mass. Histology features and immunohistochemical staining with vimentin and CD34 is helpful in making diagnosis of this orbital tumour and should be used whenever possible. Orbital SFT is generally non aggressive and treated by performing complete excision of the mass. Despite this, continuous follow up of the patient is beneficial as local recurrences have been known to occur.

References

1. Gupta A, Bansal R, Gupta V, Sharma A, Bamberg P. Ocular signs predictive of tubercular uveitis. *Am J Ophthalmol* 2010; 149(4): 562-70.
2. Babu RB, Sudharshan S, Kumarasamy N, Therese L, Biswas J. Ocular tuberculosis in acquired immunodeficiency syndrome. *Am J Ophthalmol* 2006; 142(3): 413-8.
3. Sheu SJ, Shyu JS, Chen LM, Chen YY, Chirn SC, Wang JS. Ocular manifestations of tuberculosis. *Ophthalmology* 2001; 108(9): 1580-5.
4. Bodaghi B, LeHoang P. Ocular tuberculosis. *Curr Opin Ophthalmol* 2000; 11(6): 443-8.
5. Sheu SJ. *Ocular Manifestations of Tuberculosis*. Berlin: Springer Berlin Heidelberg, 2004, 731-40.
6. Abrams J, Schlaegel TF. The role of the isoniazide therapeutic test in tuberculosis uveitis. *Am J Ophthalmol* 1982; 94(4): 511-5.
7. Wroblewski KJ, Hidayat AA, Neafie RC, Rao NA, Zapor M. Ocular tuberculosis: a clinicopathologic and molecular study. *Ophthalmology* 2011; 118(4): 772-7.
8. Bouza E, Merino P, Muñoz P, Sanchez-Carrillo C, Yáñez J, Cortés C. Ocular tuberculosis: a prospective study in general hospital. *Medicine (Baltimore)* 1997; 76(1): 53-61.
9. Gupta V, Gupta A, Rao NA. Intraocular tuberculosis--an update. *Surv Ophthalmol* 2007; 52(6): 561-87.
10. Singh R, Gupta V, Gupta A. Pattern of uveitis in a referral eye clinic in north India. *Indian J Ophthalmol*. 2004; 52(2): 121-5.
11. Wertheim MS, Mathers WD, Planck SJ, et al. In vivo confocal microscopy of keratic precipitates. *Arch Ophthalmol* 2004; 122(12): 1773-81.