

Original Research Article

Anatomical Profile and Morphometric Evaluation of Human Sacral Hiatus in North Indians

Renu Chauhan (✉), Mahindra Nagar

Department of Anatomy, University College of Medical Sciences and Guru Teg Bahadur Hospital, Dilshad Garden, Delhi-110095 India

Abstract

Successful caudal epidural block (CEB) for various gynaecological and orthopaedic procedures requires an elaborate knowledge of anatomical profile of sacral hiatus. Varied morphology of sacral hiatus is likely to influence the success rate of CEB. Scanty literature is available on the morphometry of sacral hiatus in North Indian subjects. Therefore, sacral hiatus of 60 North Indian human sacra were evaluated using Vernier calipers. Sexing of the sacra was done by calculating the sacral index. Following parameters of sacral hiatus were observed and recorded: a) Shape, b) Level of apex, c) Maximum distance between the sacral cornua, d) Length of the sacral hiatus i.e. from its apex to midpoint of its base, e) Antero-Posterior diameter at the apex of sacral hiatus. The data obtained was analyzed using SPSS software (version 18). Various shapes of sacral hiatus were observed. It was irregularly shaped in both the sexes though inverted U shaped sacral hiatus was also seen frequently in females. In males, the apex of sacral hiatus was commonly seen at the level of spinous process of 3rd sacral vertebra in males and below the level of spinous process of 4th sacral vertebra in females. The mean distance between the sacral cornua was 1.1cm : 1.2cm in males and females, respectively. Mean length of the sacral hiatus was 2cm in both sexes. Antero-posterior depth at the apex the sacral hiatus was 6mm in both the genders. The dimensions of sacral hiatus obtained in this study were inconsistent with earlier studies. Knowledge of these dimensions may help the clinicians in precisely locating sacral hiatus for successful CEB in North Indians.

Keywords: Caudal epidural block, morphometry, North Indians, sacrum, sacral hiatus, sacral cornua.

Correspondence:

Dr. Renu Chauhan, Department of Anatomy, University College of Medical Sciences and Guru Teg Bahadur Hospital, Dilshad Garden, Delhi-110095, India. Tel: 009-11-9810843551 Fax: 0091-11-22590495 Email: renuchauhan@yahoo.com

Date of submission: 18 Apr, 2015

Date of acceptance: 25 Aug, 2015

Introduction

Absence of fusion of the laminae of the fifth and occasionally fourth sacral vertebra leads to the formation of sacral hiatus (SH) (1). It can be palpated about 2 inches above the tip of the coccyx lying beneath the skin of natal cleft. It contains lower sacral and the coccygeal nerve roots, filum terminale and fibrofatty tissue (2). The SH is covered by skin, subcutaneous fatty layer, and sacrococcygeal membrane. These structures have to be pierced in order to reach the sacral canal (3). The lateral margins of the sacral hiatus are formed by the downward extensions of the inferior articular processes of the fifth sacral vertebra and its

remnants which are called the sacral cornua, form an important landmark during CEB (4). The SH has been used for administration of epidural anesthesia in obstetrics (5) as well as in orthopedic practices (3).

A detailed knowledge of the anatomical profile of SH is required for optimal access into sacral epidural space. Sometimes, it is difficult to determine the exact location of the SH for caudal epidural block, especially in adults (6,7). Anatomic basis is the cause of failure of CEB (3). Thus, understanding the anatomic variations of SH may improve the reliability of CEB (3,6). It is an established fact that morphological traits are influenced by racial variations. Moreover, there is paucity of information pertaining to anatomical variants and morphometric

details of SH in Indian subjects. The aim of the present study was to explore the anatomic profile and morphometric parameters of the SH in North Indian human dry sacra in order to facilitate correct and uncomplicated epidural accesses required for CEB.

Materials and Methods

Anatomical profile and morphometry of SH of sixty adult North Indian dry sacra with undamaged and clear SH were included in the present study. The bones were obtained from the osteology section of the Department of Anatomy, University College of Medical Sciences and Guru Teg Bahadur Hospital, Dilshad Garden, Delhi.

Following measurements were taken with the help of vernier calipers:

1. The maximum length of each sacrum i.e. the straight distance from sacral promontory in the midsagittal plane to the apex of sacrum.
2. The maximum breadth of each sacrum i.e. the distance between the lateral-most part of ala of each sacrum on either side.

The sacral index was calculated for each sacrum by the following equation :

$$\text{Sacral index} = \frac{\text{Maximum breadth of sacrum}}{\text{Maximum length of sacrum}} \times 100$$

Sacrum with sacral index $\leq 105\%$ were considered as male sacrum, whereas sacrum with sacral index $\geq 115\%$ were considered as female sacrum.

Following parameters of SH were studied (Fig. 1):

1. Shape of the SH
2. Level of the apex of SH
3. Distance between the sacral cornua i.e. the base of the SH —
4. Length of the SH i.e. from its apex to midpoint of its base |
5. Antero-posterior diameter at the apex the SH

The results of these parameters were statistically analyzed and compared with other studies.

Results

Sacral hiatus of 60 adult North Indian dry sacra with undamaged and clear SH were studied in the present investigation. The maximum length and breadth of each sacrum were measured and sacral index calculated in order to determine the sex. The sample of the study comprised 46 male sacra and 14 female sacra.

Table 1: Shape of sacral hiatus

S. No.	Shape	Male Sacra (46)	Female Sacra (14)
1.	U shaped	13	5
2.	V shaped	13	3
3.	Irregular shaped	19	5
4.	Bifid	1	1

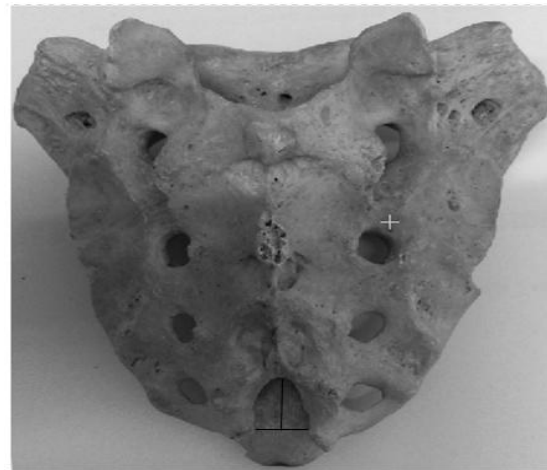


Figure 1: Dorsal aspect of sacrum showing various parameters of the sacral hiatus taken. (| - Length of sacral hiatus; — - Width of sacral hiatus)

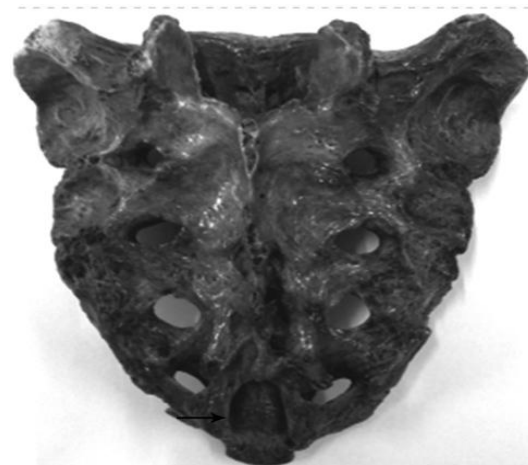


Figure 2: Dorsal aspect of sacrum showing "U" shaped sacral hiatus.

Four different shapes of SH were seen both in males and females (Table 1, Fig. 2,3,4,5). The SH was irregularly shaped in most of the sacra seen (40%) (Fig. 4). Although inverted U shaped (30%), inverted V shaped (26.67%) and bifid (3.33%) SH were also observed (Fig. 2,3,5 respectively).

Apex of the SH was seen at the level of spinous process of the third sacral vertebra (S3) in 26.7% of male sacra (Fig. 3) and below the level of spinous process of fourth sacral vertebra (S4) in female sacra (8.33%) out of the total number of sacra examined. In some sacra, the apex of SH was also observed at the level of spinous processes of second sacral vertebra (S2) (Males=3.33%, Females=3.33%), at the level of spinous processes of S4 (Males=20%, Females=5%), below the level of spinous processes of S4 (Males=23.33%, Females=8.33%), at the level of spinous process of fifth sacral vertebra (S5) (Males=1.67%, Females=1.67%) and below the level of spinous processes of S5 (Males=1.67%, Females=00%) (Table 2).

The mean length of SH i.e. from its apex to midpoint of its base was found to be 20.4 ± 08.8 mm and 20.4 ± 12.0 mm in males and females, respectively (Table 3). The mean breadth of SH at the level of sacral cornua was found to be 12.0 ± 3.2 mm and 11.6 ± 3.7 mm in males and females, respectively (Table 4). The mean depth of SH at the level of its apex was 6.2 ± 3.2 mm and 6.0 ± 2.4 mm in males and females, respectively (Table 5).

Discussion

The posterior elements of the sacral vertebral segments fuse to form a bony plate. The rudimentary spinous processes of the upper three or four sacral vertebrae primarily form the prominent median sacral crest and laminae on either side form the sacral grooves. Often, the bone anatomy of the fourth and fifth sacral vertebrae is absent in the midline resulting in an opening termed the SH (8). It carries a great importance in administration of anaesthesia for caudal epidural blocks required for perineal surgeries, orthopedic practice and



Figure 3: Dorsal aspect of sacrum showing “Inverted V” shaped sacral hiatus.



Figure 4: Dorsal aspect of sacrum showing irregularly shaped sacral hiatus



Figure 5: Dorsal aspect of sacrum showing bifid sacral hiatus

various obstetrics and gynecological procedures. Scanty literature was available on the anatomical profile and morphometry of SH in North Indians. Therefore, the present study was conducted on sixty adult human sacra (Males=46, Females=14).

Various shapes of the SH were observed in the present study. These were irregularly shaped (40%), inverted U shaped (30%), inverted V shaped (26.67%) and bifid (3.33%). The shape of SH was irregular in most of the cases in the present study. Contrarily, Kumar et al. and Patel et al. found no irregularly shaped SH in their study (9,10). Irregularly shaped SH was reported in 14.1% cases by Nagar (11), and in 9.31% cases by Shewale et al. (12). Dumb-bell shaped, complete spina bifida or absent SH were also found in the study of Kumar et al. (9), Patel et al. (10), Nagar (11) and Shewale et al. (12) whereas these were not encountered in the current study.

The apex of the SH was most commonly observed at the level of third sacral spinous process in male sacra (26.7%) and below the level of spinous process of S4 in the female sacra (8.33%) out of the total number of sacra examined in the present study. However, Kumar et al. (9) found the apex of SH at the level of spinous process of S4 in 76.23% cases. Patel et al. (10) reported the level of apex of SH at the spinous process of S4 in 59.33% of sacra. Sekiguchi et al. (3), Nagar (11), Shewale et al. (12), Shinohara (13), Trotter and Lanier (14) and Kumar et al. (15) also found the level of apex of SH at the spinous process of S4 in 55.9%, 66.5%, 75%, 64%, 65% and 51.19% of sacra, respectively. Epigenetic variation could possibly be the reason for the difference between the findings of these authors and the present study.

The mean length of SH seen in the current study was 20.4 ± 8.8 mm and 20.4 ± 12.0 mm in male and female sacra, respectively. When this data was compared with the studies of Trotter and Lanier (14), Trotter and Letterman (16) and Lanier et al. (17), a difference of 2-5 mm was obtained. The difference between their work and the present study could be a regional variation. The present study was in accordance to the work of Kumar et al. (9) and Nagar (11) suggesting that samples considered from similar population group does not show much variation.

The mean breadth of SH at the level of sacral cornua was 12.0 ± 3.2 mm and 11.6 ± 3.7 mm in males and females, respectively. These dimensions were compared with reports of previous studies. Data obtained in the current study was at variance with the study of Trotter and Letterman (16) and Lanier et al. (17) because of difference of population group studied. Present study was consistent with the study of Kumar et al. (9), Nagar (11) and Park et al. (18) as their work was conducted on similar population.

The mean depth of SH in the current study was 6.2 ± 3.2 mm and 6.0 ± 2.4 mm in males and females respectively. Its values were compared with reports of earlier studies. The mean depth of the SH obtained in the current study was similar to the findings of Lanier et al. (17) and Sekiguchi et al. (3). However, our findings are not in accordance with the studies of Trotter and Letterman (16), Kumar et al. (9), Nagar (11) and Patel et al. (10).

The incidence of variations of SH may be due to genetic and racial factors. Understanding of these variations may improve the success rate of CEB. In the present study, elongated, dumb bell shaped and absent SH were not encountered. It is suggested that insertion of a needle into the SH for CEB should be performed at its

Table 2: Location of apex of sacral hiatus

S. No.	Level of apex of sacral hiatus	Male Sacra	Female Sacra
1.	At the level of S2	2	2
2.	At the level of S3	16	3
3.	At the level of S4	12	3
4.	Below the level of S4	14	5
5.	At the level of S5	1	1
6.	Below the level of S5	1	0

Table 3: Length of sacral hiatus

S.No.	Gender	No. of Sacra	Mean mm	Standard deviation	Standard Error mean
1.	Female	14	20.43	11.992	0.3205
2.	Male	46	20.40	08.754	0.1291

Table 4: Breadth of sacral hiatus at the level of sacral cornua

S.No.	Gender	No. of Sacra	Mean mm	Standard deviation	Standard Error mean
1.	Female	14	11.64	3.734	0.998
2.	Male	46	11.15	3.190	0.470

Table 5: Depth of sacral hiatus at the level of its apex

S.No.	Gender	No. of Sacra	Mean mm	Standard deviation	Standard Error mean
1.	Female	14	6.00	2.449	0.655
2.	Male	46	6.22	3.183	0.469

base in view of the anatomic variations of its apex. The present study is an attempt to provide basic anatomical data pertaining to sacral hiatus of North Indian population.

Conclusion

Admittedly, in view of small sample size of female sacra, it is rather hard to comment on the sexual dimorphism of the sacral hiatus. However, it is expected that the results of present investigation would constitute data of reference for future researchers.

References

1. Standring S. Gray's Anatomy - The anatomical basis of clinical practice. 40th Ed. UK: Churchill Livingstone Edinburgh, 2008, pp-724.
2. Newell RL. The Back - The Anatomical basis of clinical practice. London: Churchill Livingstone Elsevier, 2008, pp-724-28.
3. Sekiguchi M, Yabuki S, Saton K, Kikuchi S. An anatomical study of the sacral hiatus: a basis for successful caudal epidural block. Clin J Pain 2004; 20: 51-4.
4. Waldman SD. Caudal epidural block: Prone position-Atlas of interventional pain management. 2nd Ed. Philadelphia: Saunders, 2004, pp-380-92.
5. Edwards WB, Hingson RA. Continuous caudal anaesthesia in obstetrics. Am J Surg 1942; 57: 459-64.
6. Senoglu N, Senoglu M, Oksuz H et al. Landmarks of the sacral hiatus for caudal epidural block: an anatomical study. Br J Anaesth 2005; 95(5): 692-5.
7. Aggarwal A, Aggarwal A, Harjeet, Sahni D. Morphometry of sacral hiatus and its clinical relevance in caudal epidural block. Surg Radiol Anat 2009; 31(10): 739-800.
8. Cheng JS, Song JK. Anatomy of the sacrum. Neurosurg Focus 2003; 15: 1-4.
9. Kumar V, Pandey SN, Bajpai RN, Jain PN, Longia GS. Morphometrical study of sacral hiatus. J Anat Soc India 1992; 42(1): 7-13.
10. Patel Z, Thummar B, Rathod SP, Singel TC, Patel S, Zalawadia A. Multicentric morphometrical study of dry human sacrum of Indian population in Gujrat region. NJIRM 2011; 2(2): 31-5.
11. Nagar SK. A study of sacral hiatus in dry human sacra. J Anat Soc India 2004; 53(2): 18-21.
12. Shewale SN, Mohammad L, Kulkarni PR, Chaya VD. Morphological and morphometrical study of sacral hiatus. I J Recent Trends in Sci Tech 2013; 6(1): 48-52.
13. Shinohara H. The size and position of the sacral hiatus in man. Okajinas Folia Anat Jpn 1999; 76 (2-3): 89-93.
14. Trotter M and Lanier PE. Hiatus canalis sacralis in American whites and Negroes. Hum Biol 1945; 17: 368-81.
15. Kumar V, Panday SN, Bajpai RN, Srivastava RK, Longia GS. Termination level of dural sac in the sacral canal. J Anat Soc India 1994; 43(2): 137-142.
16. Trotter M and Letterman GS. Variation of female sacrum: their significance in continuous caudal anesthesia. Surg Gynecol Obstet 1944; 78(4): 419-24.
17. Lainer VS, McKnight HE, Trotter M. Caudal analgesia: an experimental and anatomical study. Am J Obstet Gynecol 1944; 47(5): 633-41.
18. Park JH, Koo BN, Kim JY, Cho JE, Kim WO, Kil HK. Determination of the optimal angle for needle insertion during caudal block in children using ultrasound imaging. Anesthesia 2006; 61(10): 946-9.