

Case Report

A Rare Case of Presacral Paraganglioma Presenting with Hypertensive Encephalopathy

Dhiraj KB, Mamatha B (✉)

Department of Pediatric Surgery, Vydehi Institute of Medical Science and Research Centre Whitefield, 66 Bangalore, India.

Abstract

Paragangliomas are exceptionally rare tumors in children of neural crest origin. Our case report represents an extremely rare location for paraganglioma including its imaging features, perioperative challenges and histopathological characteristics. In the present case, a 10-year-old boy had headache and blurring of vision for four years but was not diagnosed until he came with malignant hypertension and hypertensive encephalopathy. The symptoms raised urinary catecholamines and CT findings confirmed the diagnosis of a functioning paraganglioma in presacral region. Challenges during surgery are to control the fluctuating blood pressure which may suddenly rise during tumor handling and suddenly fall following its removal. The unusual location of the tumor in pararectal region also made surgical resection difficult. Paragangliomas are rare and should be kept in mind while evaluating a child with hypertension and complete excision is the treatment of choice.

Keywords: Presacralpararectal paraganglioma, malignant hypertension, hypertensive encephalopathy, perioperative challenges, complete excision

Correspondence:

Mamatha B, Department of Pediatric surgery, Vydehi Institute of Medical Science and Research Centre Whitefield, Bangalore -66
Tel: 919886743394 Email: mamathanaveen3@gmail.com/dhirajkb1973@gmail.com

Date of submission: 21 May, 2014

Date of acceptance: 21 Oct, 2014

Introduction

Paragangliomas are catecholamine secreting tumors that are found along sympathetic and parasympathetic chain. Tumors that originate from adrenal medulla are defined as pheochromocytoma whereas tumors located in extra adrenal positions are termed paragangliomas (1). This is a rare case report of paraganglioma in presacral region with only about five cases being reported in this location so far (2-6). The patient was from a remote place and was not diagnosed till he came with hypertensive encephalopathy.

Case Report

A 10-year-old Bangladeshi boy came to us with history of headache and blurring of vision on and off since 4 years. Patient had one episode of generalized

seizures and loss of consciousness for which he was taken to a local hospital and diagnosed to have hypertensive encephalopathy with blood pressure of 180/130. Patient was treated with mannitol, diuretics and came to us for further evaluation for malignant hypertension. Blood sugars, serum electrolytes calcium, phosphorous etc were normal. The liver and kidney parameters were normal and renal artery Doppler was normal. The patient had hypertensive retinopathy and echocardiogram revealed a left ventricular hypertrophy consistent with long standing hypertension.

On subsequent evaluation for hypertension he was found to have raised 24 hr urinary epinephrine (27microgram/24hrs, normal < 8microgram/24hrs), norepinephrine (1307microgm/ 24 hrs, normal < 50microgm/hr) and plasma normetanephrine (848pg/ml, normal < 180pg/ml). With a suspicion of

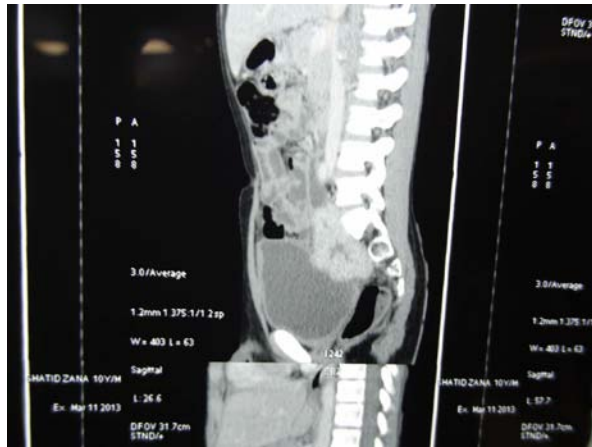

Figure 1

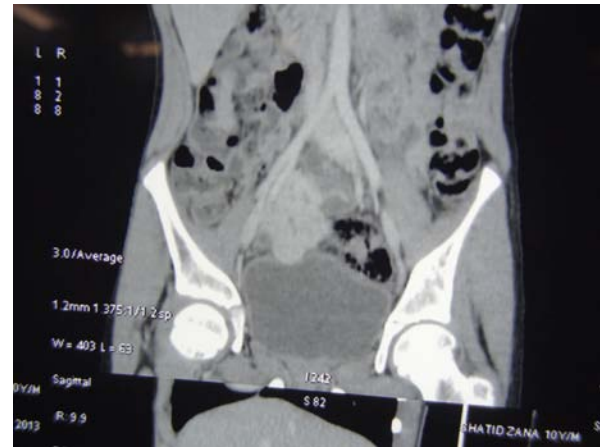

Figure 2

Figure 1 and 2: CT Abdomen and pelvis was performed which revealed a non enhancing hypodense mass of 5x 4 x 6.7cm in right pelvis , posterior to bladder causing indentation over posterior wall of bladder adjacent to rectum extending to pre sacral region with well-maintained fat planes.

pheochromocytoma CT abdomen and pelvis was performed which revealed a non enhancing hypodense mass of 5 x 4 x 6.7 cm in right pelvis , posterior to bladder causing indentation over posterior wall of bladder adjacent to rectum extending to pre sacral region with well maintained fat planes (Fig. 1). Patient was initially started on alfa blocker prazosin and later amlong and atenolol were added with which his blood pressure stabilized to 110/84mmHg. Two days prior to surgery patient was given plasma expanders to minimize the postural hypotension accompanying alfa blockade and to expand his volume as precautionary measure to counteract for the expected hypotension in immediate post-op period.

During surgery an extremely vascular irregular mass of 6 x 5 cm was seen over the right common iliac and internal iliac vessel extending into presacral region and pararectal space (Fig. 2). Right ureter was adherent to the mass laterally and had to be released carefully. Once tumor was removed there was hypotension for which norepinephrine drip was started, was continued for 36 hrs, tapered and stopped. Histopathology confirmed it was a paraganglioma with a well circumscribed fibro connective capsule, tumor cells in typical nesting pattern surrounded by sustentacular cells. There was no capsular or lymphovascular invasion. Immunoreactivity was positive for chromogranin and S-100 showing the existence of sustentacular cells. Post-operatively, patient on 6 months follow-up is normotensive with normal urinary catecholamines and MIBG scan done shows no pathological uptake.

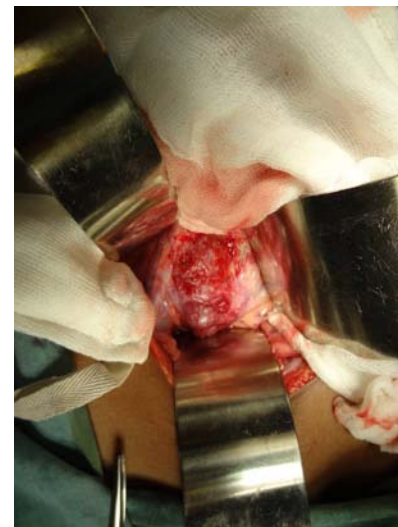


Figure 3: Extremely vascular irregular mass of 6 x 5cm seen over the right common iliac and internal iliac vessel extending into presacral region and pararectal space.

Discussion

Chromaffin tumors are exceptionally rare tumors in children with an incidence of 10% that of adults. They account for < 0.5% of children with hypertension and must be considered once other causes are eliminated (7). Although well described for adult population, diagnosis and treatment of these rare tumors is poorly defined in pediatric literature.

Common tumor locations of paragangliomas are organ of Zuckerkandl, bladder wall, heart, mediastinum,

carotid and glomusjugulare bodies. The majority are within abdomen and are associated with coeliac, superior and inferior mesenteric ganglia and pelvic location is rare (2%) (4). The paraganglioma in our case is likely to have originated from sympathetic chain in pararectal region or pelvic side wall.

There are some genetic conditions like familial multiple endocrine neoplasia 2, Von hippel landau disease and neurofibromatosis type 1 with increased risk of paragangliomas. There is also a group of familial paraganglionosis syndrome resulting from mutations of tumor suppressor genes (SDHD, SDHB, SDHC) (8).

Functioning paragangliomas and pheochromocytomas have a similar clinical presentation with episodic headache, sweating, tachycardia accompanied with paroxysmal hypertension. But in contrast to adults most children present with sustained hypertension. Though our child had episodic headache and blurring of vision since 4 years he was not diagnosed till he developed malignant hypertension and its complications like increased intracranial pressure and encephalopathy. Continuously elevated BP “breaks through” cerebral autoregulation (Bayliss response) and causes vasodilation, resulting in hypoperfusion and ischemia, which leads to hypertensive encephalopathy.

It is essential to differentiate these tumors from more common childhood neoplasms like neuroblastoma and wilms. Failure to differentiate may cause hemodynamic lability in perioperative period due to failure to achieve appropriate alfablockade prior to beta adrenergic blockade (1).

To localize the paraganglioma imaging with MRI / CT and scintigraphy are done. Scintigraphy using an analogue of noradrenaline, MIBG is the best study to screen for metastasis or recurrence, but newest technique 18F- DOPA PET imaging offers even higher accuracy than MIBG (4).

The incidence of paraganglioma is higher in children than adults (60% vs. 10-40%) (9). Most of the paragangliomas and pheochromocytomas are benign with approximately 10% of pheochromocytoma and 15-35% of paragangliomas being malignant in children. According to WHO classification of endocrine tumors the clinical and histological distinction between benign and malignant tumor is not clear, the definitive diagnosis of malignancy is based solely on presence of metastases, characteristically to lung, liver and lymph nodes or by local invasion. Hence post operatively urine and plasma metanephrine

and catecholamine should be checked annually (9). As paragangliomas have a higher chance of malignancy but as yet no pathological markers predict malignancy, it is recommended they be followed up indefinitely (10).

This case report is unusual and has several important implications. Our child had headache and blurring of vision for 4 years but was not diagnosed until he came with hypertensive encephalopathy. The emphasis is on simple measurement of blood pressure would have helped in early detection and prevent fatal complications. Patient symptoms raised urinary catecholamines and CT findings confirmed the diagnosis of a functioning paraganglioma in presacral region. The unusual location of this tumor (close to ureter, bladder and rectum), made surgery challenging. Challenges during surgery is to control the fluctuating blood pressure which may suddenly raise during tumor handling and suddenly fall just after it is removed like in our case. If diagnosed early and removed surgically the prognosis is good, but if goes undiagnosed it can be fatal.

Conclusion

Paragangliomas are rare and should be kept in mind while evaluating a child with hypertension. Once diagnosis is confirmed by biochemical tests and imaging techniques, surgical resection is the treatment of choice after controlling the catecholamine related symptoms. Complete excision is important because histological differentiation between benign and malignant tumor is not clear, and hence also requiring a close and indefinite follow up.

References

1. Pham TH, Moir C, Thompson GB, et al. Pheochromocytoma and paraganglioma in children: A Review of Medical and Surgical Management at a tertiary care centre. *Pediatrics* 2006; 118(3): 1109- 17.
2. Genevay M, McKee T, Zimmer G, Cathomas G, Guillou L. Digestive PEGomas: a solution when the diagnosis fails to “fit”. *Ann Diagn Pathol* 2004; 8(6): 367-72.
3. Royo P, de Luis E, Manero MG, Velloso MJ, Toledo G, Alcázar JL. Pelvic paraganglioma. *J Ultrasound Med* 2007; 26(2): 261-5.
4. Bhatt S, Vanderlinde S, Farag R, Dogra VS. Pararectal paraganglioma. *Br J Radiol* 2007; 80(958): e253-6.

5. Bosch FJ, Goedhals J, De Lange W, Ackermann M, Koning JMM. A pelvic paraganglioma presenting as hypertensive emergency in pregnancy. *JEMDSA* 2012; 17(3): 145-7.
6. Di Daniele N, Canale MP, Tesauro M, et al. Preoperative Embolization Reduces the Risk of Catecholamines Release at the Time of Surgical Excision of Large Pelvic Extra-Adrenal Sympathetic Paraganglioma. *Case Rep Endocrinol* 2012; 2012: 481328.
7. Michael GC and Mauricio AE, Jr. Adrenal tumors. *Pediatric Surgery*. 7th edition edited by, Arnold .GC, Scott Adzick N, Thomas M. Krummel, Jean Martin Laberge, Robert.C. Shamberger, Anthony A. Caldmone. Philadelphia: Elsevier Saunders, 2012, pp-557-61.
8. FitzGerald SC, Gingell Littlejohn M, Parnaby CN, Connell JM, O'Dwyer PJ. Abdominal paraganglioma: Analysis of surgeon's experience. *WJOES* 2011; 3(2): 55-8.
9. Solcia ESLH. Histological typing of endocrine tumors: WHO Classification, International Histological Classification of Tumors. Berlin: Springer, 2000. pp-viii, 160.
10. Poulin PF, Gimenez-Roqueplo AP. Initial work up and long term follow up in patients with Pheochromocytomas and Paragangliomas. *Best Pract Res Clin Endocrinol Metab* 2006; 20(3): 421-34.