

Case Report

Unusual Morphology of the Axillary Vein Forming a Loop around the Lateral Thoracic Artery

Sudarshan S, Naveen K, Srinivasa RS (✉), Venu MN

Department of Anatomy, Melaka Manipal Medical College, Manipal University, Manipal, 567104 Karnataka, India.

Abstract

Venous anomalies of the upper limb are not uncommon. However, unusual anomaly of the axillary vein forming a loop around a branch of the axillary artery has seldom been reported in the literature. In the present case, we report a rare case of perforation of the axillary vein (AV) by the lateral thoracic artery in the right axilla. It was noted in an approximately 65-year-old male cadaver of South Indian origin, during regular laboratory teaching to the medical undergraduates. The formation and termination of AV were found to be normal. The knowledge about the occurrence of the possible anomalies of AV is clinically important to avoid complications during the invasive therapeutic surgical procedures. It is also important during the diagnostic procedures such as ultrasound imaging and venography.

Keywords: Perforation, axillary vein, cadaver, axillary artery, dissection

Correspondence:

Srinivasa Rao Sirasanagandla, Department of Anatomy, Melaka Manipal Medical College, Manipal University, Manipal, 567104 Karnataka, India. Tel: +91 820 2922644 Fax: +91-820-2571905 Email: seenaih.anat@gmail.com

Date of submission: 5 Feb, 2014

Date of acceptance: 25 July, 2014

Introduction

Axillary vein (AV) is the major vein of the upper limb, formed by the basilic vein at the lower border of the teres major. Usually, it courses on the medial side of the axillary artery (AA). At the level of outer border of first rib, AV terminates as subclavian vein. It receives the tributaries of the veins that accompany the branches of the AA. Fenestration of the AV is a rare anomaly. Earlier two different cases of fenestration of AV by the trunk of AA and lateral thoracic artery (LTA) have been reported (1, 2). Perforation of AV by the medial cutaneous nerve of forearm is also reported (3). Fenestration of other veins such as subclavian and internal jugular veins by the phrenic nerve (4) and accessory nerve (5), respectively has been observed. The anatomic variants of the AV are clinically important as it is used in various invasive therapeutic procedures. In the present case, we report a case of fenestrated AV by the LTA and discuss its clinical significance and morphology.

Case Report

During regular dissections for medical undergraduates, we came across a rare anatomical variation in the right axilla. It was observed in an approximately 65-year-old male cadaver of South Indian origin. Basilic vein continued as AV at the lower border of the teres major muscle. After formation, it ran on the medial side of the axillary artery. AV was found to be fenestrated, as it was perforated by a branch of the axillary artery, the lateral thoracic artery. Lateral thoracic artery took origin from the 2nd part of the axillary artery, at the lower border of the pectoralis minor muscle. Then, it passed medially through the loop formed by the AV and divided into branches to supply the pectoral region (Fig. 1). Further, no associated variations of the axillary artery were observed.

Discussion

Duplication is the commonly reported anomaly of the AV (6). The occurrence of fenestration in the AV is

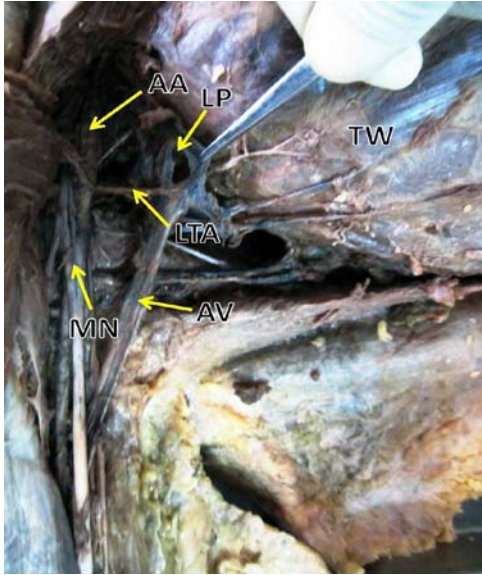


Figure 1: Dissection of right axilla showing the perforation of axillary vein (AV) by the lateral thoracic artery (LTA), branch of second part of axillary artery (AA). MN: median nerve, LP: loop in the AV, TW: thoracic wall.

rarely reported in the literature (1, 2). Hadimani et al. have reported a cadaveric case in which AV is fenestrated by the trunk of the AA (1). In their case, AA gave a collateral axillary arterial trunk from its second part. A study by Mahajan et al. has observed fenestration of the AV in one case out of the 40 dissected cadavers (2). In their case, AV was fenestrated by the LTA. Contrary to their observation, in the present case AV presented a visible loop for the passage of LTA.

In embryonic life, mesenchymal condensation of developing limb bud gives rise to AV (7). Formation of superficial and deep vessels in the limb is a complex processes wherein some anastomosis may develop between these vessels or others may not develop or some may also regress. This complex process is regulated by haemodynamic factors. The AA and its branches develop from the seventh cervical segmental artery. Unusual anomaly of AV observed in the present case could be due to the entrapment of the branch of AA within the venous plexus of the primitive AV.

Management of breast cancer by axially lymph node dissection needs the identification of the AV (8). Importance of AV in the central venous line approach in severely burned patients has been demonstrated (9). AV is recommended for the safe venous cannulation due to the non-overlapping and having considerable distance between axillary vessels (10). However, central venous access through AV is preferred using

ultrasound (10). Clinical importance of AV in the implantation of cardioverter defibrillator (ICD) and pacemaker (11) and also in the assessment of central thoracic venous thrombosis (12) has been demonstrated. The knowledge of the anatomic variants of AV plays a crucial while performing the surgical interventional procedures.

AV with perforation is more prone to the formation of thrombus when it is subjected to trauma and even during surgical interventions (13). During the surgical approaches of the AV, the perforated LTA may get damaged. As the anomalies of the veins usually detected during the surgeries or preoperative diagnostic procedures, the knowledge about their occurrence is important to minimize the iatrogenic injuries and to avoid confusion during imaging and venography procedures. In conclusion, the perforation of the AV by the AA branch is rarely reported in the literature. Documentation of unusual morphology of the AV as reported here may be useful clinically.

References

1. Hadimani S, Desai SD, Bagoji IB, Patil BS. Fenestration of axillary vein by a variant axillary artery. *Kathmandu Univ Med J (KUMJ)* 2013; 11(42): 162-4.
2. Mahajan A, Rana, KK, Saha S. Perforation of axillary vein by a branch of the axillary artery-an anatomical study. *Int J Morphol* 2012; 30(2): 579-82.
3. Roy TS, Sharma S. Axillary vein perforation by the medial cutaneous nerve of the forearm. *Clin Anat* 2004; 17(4): 300-2.
4. Thakur JS, Sharma DR, Mohindroo NK. Double fenestration of the internal jugular vein: a rare anatomic variant. *Ear Nose Throat J* 2012; 91(10): 420,427.
5. Gardiner KJ, Irvine BW, Murray A. Anomalous relationship of the spinal accessory nerve to the internal jugular vein. *Clin Anat* 2002; 15(1): 62-3.
6. Yang HJ, Gil YC, Jin JD, Cho H, Kim H, Lee HY. Novel findings of the anatomy and variations of the axillary vein and its tributaries. *Clin Anat* 2012; 25(7): 893-902.
7. O'Rahilly R, Muller F. *Human embryology and teratology*. 2nd ed. New York: Wiley Liss, 1996, pp-354.

8. Wright MJ, Long JN. Surgical Treatment of Breast Cancer, 2011. Available in: <http://emedicine.medscape.com/article/1276001-overview>.
9. Andel H, Rab M, Felfernig M, et al. The axillary vein central venous catheter in severely burned patients. *Burns* 1999; 25(8): 753-6.
10. Galloway S, Bodenham A. Ultrasound imaging of the axillary vein-anatomical basis for central venous access. *Br J Anaesth* 2003; 90(5): 589-95.
11. Seto AH, Jolly A, Salcedo J. Ultrasound-guided venous access for pacemakers and defibrillators. *J Cardiovasc Electrophysiol* 2013; 24(3): 370-4.
12. Raju S. Surgical treatment of deep venous vascular incompetence. In: Rutherford RB, editor. *Vascular surgery*. 5th ed. Philadelphia: W.B. Saunders, 2000, pp 2037-49.
13. Chang CW, Oh SJ. Medial antebrachial cutaneous neuropathy: case report. *Electromyogr Clin Neurophysiol* 1988; 28(1): 3-5.