

## Case Report

# A Rare Unilateral Variation in the Course of External and Internal Carotid Arteries

Satheesha BN, Srinivasa RS (✉), Swamy RS, Deepthinath R, Sudarshan S, Naveen K

Department of Anatomy, Melaka Manipal Medical College (Manipal Campus), Manipal University, Manipal, Karnataka State, 567104, India.

### Abstract

Vascular variations in the neck region are not uncommon. Knowledge of incidence of morphological variations in the course and branching of the carotid arteries is important for radiological interpretation and surgical correction when they are symptomatic. Internal carotid artery (ICA) is known to show elongation in its extra cranial course. Previous studies have demonstrated the incidence and clinical symptoms of this morphological entity. However, the occurrence of elongation and looping of the external carotid artery (ECA) is seldom reported in the literature. During regular dissections, we came across a rare case of unilateral morphological variation of both ECA and ICA, in a male cadaver aged about 55 years. ICA presented a curved course with convexity directed posteriorly, at the level of the C2-C3 vertebrae. ECA presented a pronounced kinking or coiling, one inch below the level of the angle of the mandible. In addition, a linguo-facial trunk arising from the ECA also presented a pronounced kinking throughout its entire length.

**Keywords:** Internal carotid artery, external carotid artery, common carotid artery, kinking, coiling.

### Correspondence:

Srinivasa Rao Sirasanagandla, Melaka Manipal Medical College (Manipal Campus), Manipal University, Manipal, Karnataka State, 567104, India. Tel: +91 820 2922644 Fax: +91-820-2571905 Email: seenaih.anat@gmail.com

Date of submission: 23 Jan, 2014

Date of acceptance: 10 June, 2014

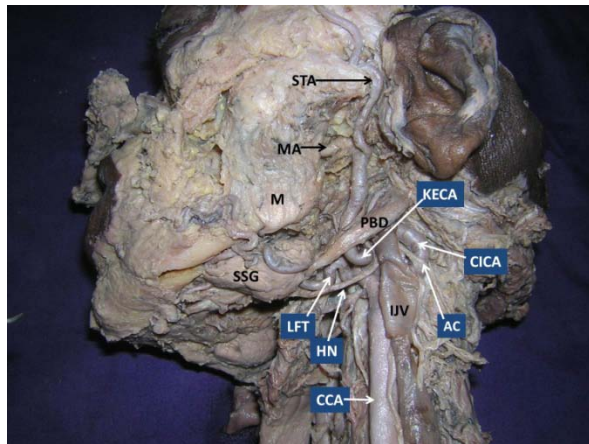
### Introduction

Common carotid arteries chiefly supply the head and neck region. Each common carotid artery bifurcates into external carotid artery (ECA) and internal carotid artery (ICA). According to classical text book description, the carotid arteries run straight in the neck region (1). Rarely, they show coiling in their course (2). Compared to ECA, ICA more frequently presents such morphological entity (3). Usually, ICA begins at the level of the lamina of the upper border of the thyroid cartilage and enters into the temporal bone. If the distance between these two points is lesser than the vessel length, it leads to coiling, looping and kinking of the vessel (4). However, these conditions are thought to occur due to the benign angiopathy (5) or neurological complications (6) or also considered as congenital anomalies (3). The knowledge of morphological variants of carotid arteries is important while

performing procedures such as tonsillectomy, peritonsillar abscess drainage, soft palate impalement injuries, adenoidectomy and velopharyngoplasty (3). Herein, we report a unilateral variation of both the ECA and ICA in the neck region, and discuss its clinical importance.

### Case Report

During regular laboratory dissections for medical undergraduates, we came across a rare unilateral morphological variation in the course and branches of the carotid arteries. It was observed in a formalin embalmed male cadaver of South Indian origin, aged approximately 55 years. The variation was observed on the left side of the neck and was unilateral. The common carotid artery divided into ECA and ICA, at the level of upper border of the thyroid cartilage. The proximal segment of the ICA presented a 'posterior

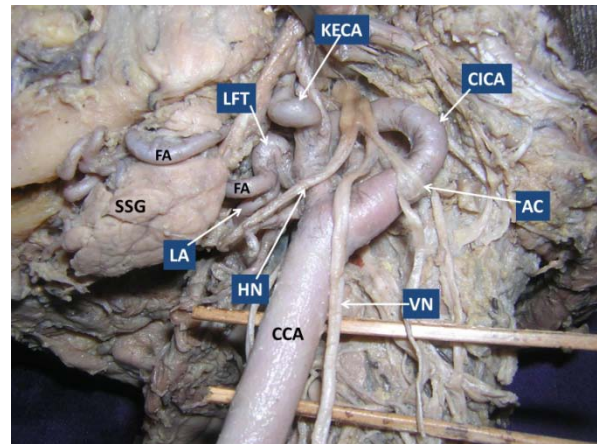


**Figure 1:** Dissection of left side of the neck showing the variations of the carotid arteries. (KECA: kink of external carotid artery, CICA: curve of internal carotid artery, AC: ansa cervicalis, IJV: internal jugular vein, CCA: common carotid artery, HN: hypoglossal nerve, LFT: linguo-facial trunk, PBD: posterior belly of digastric, SSG: submandibular salivary gland, M: masseter, MA: maxillary artery, STA: superficial temporal artery)

curve' and the convexity of the curve was directed posteriorly. This 'posterior curve' was situated at the level of C2-C3 vertebrae, immediately above the bifurcation of the CCA. The curve passed backwards, medial to the internal jugular vein and was crossed superficially by the vagus nerve (Fig. 1 and 2). From the point of bifurcation of CCA, the ECA ran upwards, anterior to the ICA. After a short distance, it showed a pronounced 'kinking' one inch below the level of the angle of the mandible (just below the posterior belly of the digastric muscle), then ascended behind the neck of the mandible and terminated into maxillary and superficial temporal arteries (Fig. 1).

## Discussion

Classically, the carotid arterial system presents constant origin and course in the superior mediastinum and neck (1). When compared to CCA and ECA, ICA frequently shows variations in its course and forms coiling, looping and kinking or tortuosity (3). In 1951, Riser et al (7) have demonstrated the association between the carotid kinking and cerebrovascular insufficiency. Variations of ICA are could be due to developmental errors of aortic arteries (3) as looping and kinking is also reported to occur in the infants and fetuses (8). During the ICA development, usually major portions of segmental arteries that contribute to its formation disappear. Rarely they may persist and give rise to the anomalous branches of the ICA (9). Any developmental errors in the descent of heart and great vessels into superior mediastinum or failure of



**Figure 2:** Closer view of the variations of the carotid arteries. Internal jugular vein has been reflected. (KECA: kink of external carotid artery, CICA: curve of internal carotid artery, AC: ansa cervicalis, CCA: common carotid artery, HN: hypoglossal nerve, LFT: kink of linguo-facial trunk, LA: lingual artery, FA: facial artery, SSG: submandibular salivary gland, VN: vagus nerve)

absorption of the third aortic arch or the upper intersegmental artery result in the elongation of the ICA (10).

Though the morphological variants of the course of the ICA are frequently defined by using different terms coiling, looping, kinking and S or C shaped elongation, tortuosity is appropriate term that can replaces others (11). Paulsen et al. (3) have classified the course of ICA into four types. According to them, if the deviation from the vertical axis is less than  $15^\circ$ , it is straight. If the deviation is greater than  $15^\circ$  and lesser than  $70^\circ$ , then it is curved. If the deviation lies between the  $90^\circ$  and  $145^\circ$ , then it is classified as coiled or kinked. If the deviation is  $360^\circ$ , it is looped. Further, they subdivided the curving into medial, lateral or ventrodorsal. In the same study, 65-70% of cases presented straight course, 25-28% of cases had curved course and 5-7% of cases had kinking or coiling of ICA. Unusual looping of the ICA in relation to an enlarged lymph node has been observed in a cadaver (12). Tortuosity of the ICA is rarely associated with clinical symptoms (10). The variants of the ICA may lead to degenerative alterations in the blood vessels with increase in age (3). The close relationship of the tortuous ICA with pharyngeal wall can cause difficulties in swallowing and speech and it may lead to difficulty to surgeons in this area (3). Individuals with tortuous ICA may present with focal neurological and hemispheric symptoms (3).

Though the elongation, coiling, looping or kinking of ICA is common, it is extremely rare to have these

variations with respect to the ECA (13). A cadaveric case of ECA forming S shaped loop has also been reported (13). The developmental arrest in the shifting of heart and large blood vessels into the superior mediastinum or shifting of origin from the aortic sac to third aortic arch may attribute to the formation of kinks in the ECA (10). Early diagnosis of kinking of the ECA is clinically important as it is frequently associated with stenosis, vasculitis, atropic dilation and arteriosclerosis (14).

### Conclusion

Though posterior curvature of the ICA is not an uncommon finding, the occurrence of concurrent variations in the course of ICA and ECA reported here is seldom reported in the literature. Documentation of this rare variation may be of clinical importance while performing the surgical, imaging and invasive techniques involving the carotid vessels.

### References

1. Gray H. Cardiovascular: internal carotid artery. In Gray's Anatomy (ed. Williams PL, Bannister LH, Berry MM, Collins P, Dyson M, Dussek JE et al.) 38th edn. Edinburgh: Churchill Livingstone, 1995, pp 1523-9.
2. Pellegrino L, Prencipe G, Vairo F. [Dolicho-arteriopathies (Kinking, Coiling, Tortuosity) of the Carotid arteries: Study by color Doppler Ultrasonography]. *Minerva Cardioangiolog* 1998; 46(3): 69-76.
3. Paulsen F, Tillmann B, Christofides C, Richter W, Koebke J. Curving and looping of the internal carotid artery in relation to the pharynx: frequency, embryology and clinical implications. *J Anat* 2000; 197(Pt 3):373-81.
4. Szekely G, Csecsei GI. Anteposition of the internal carotid artery for surgical treatment of kinking. *Surg Neurol* 2001; 56(2): 124-6.
5. Perdue GD, Barreca JP, Smith RB, King OW. The significance of elongation and angulation of the carotid artery: a negative review. *Surgery* 1975; 77(1): 45-52.
6. Ozbek C, Yetkin U, Ozelci A, Yurekli, Gürbüz A. Coiling of extracranial internal carotid artery as a cause of neurologic deficits. *The Internet Journal of Thoracic and Cardiovascular Surgery* 2007; 10(1): 3.
7. Riser M, Geraud J, Ducoudray J, ribaut L. Long internal carotid artery with vertigo syndrome. *Rev Neurol (Paris)* 1951; 85(2):145-7.
8. Sarkari NB, Holmes JM, Bickerstaff ER. Neurological manifestations associated with internal carotid loops and kinks in children. *J Neurol Neurosurg Psychiatr* 1970; 33(2): 194-200.
9. Caldemeyer KS, Carrico JB, Mathews VP. The radiology and embryology of anomalous arteries of the head and neck. *AJR* 1998; 170(1): 197-203.
10. Kelly AB. Tortuosity of the internal carotid artery in relation to the pharynx. *J Laryngol Otol* 1925; 40:15-22.
11. Fazan VPS, Ribeiro RA, Oliveira MAS, Caetano AG, Rodrigues Filho OA. Tortuosity of the internal carotid artery cervical course: case reports and literature review. *Braz J Morphol Sci* 2007; 24(4): 244-7.
12. Satheesha NB. Unusual looping of the internal carotid artery in relation to an enlarged lymph node. *IJAV* 2010; 3: 84-5.
13. Vinaitha D, Anandhi KS, Saran RS, Lakshmi R, Subramaniam A. Bifurcation of the common carotid artery and looping of the external carotid artery-a case report. *J Clin Diagn Res* 2012; 6(3): 462-4.
14. Milic DJ, Jankovic MM, Zivic SS, Jankovic RJ. Coiling of the left common carotid artery as a cause of transient ischemic attacks. *J Vasc Surg* 2007; 45(2): 411-3.