

## Case Report

# Radiation Induced Sarcoma: A Risk That is Almost Forgotten

Ruhi Fadzlyana J<sup>1,2</sup>, Nani Harlina ML<sup>1</sup>, Saladina Jaszle J<sup>1</sup>, Rohaizak M (✉)<sup>1</sup>

<sup>1</sup>Breast & Endocrine Unit, Department of Surgery, Universiti Kebangsaan Malaysia Medical Centre, Jalan Yaacob Latif, Bandar Tun Razak 56000 Cheras, Kuala Lumpur, Malaysia.

<sup>2</sup>Faculty of Medicine & Health Sciences, Universiti Sains Islam Malaysia, Level 13, Menara B, Persiaran MPAJ, Jalan Pandan Utama, Pandan Indah, 55100 Kuala Lumpur, Malaysia.

### Abstract

Radiotherapy has been widely use as an adjuvant therapy in the breast cancer management. The usage has increased the incidence of radiation induce sarcoma. We here present a case of radiation induce sarcoma of the axilla following mastectomy and axillary lymph node dissection for infiltrating ductal carcinoma.

**Keywords:** Breast carcinoma, diagnosis, radiation, sarcoma, radiotherapy

### Correspondence:

Prof. Dr. Rohaizak Muhammad, Breast & Endocrine Unit, Department of Surgery, Universiti Kebangsaan Malaysia Medical Centre, Jalan Yaacob Latif, Bandar Tun Razak, 56000 Cheras, Kuala Lumpur, Malaysia. Tel: +60391457500 Fax: +60391456688 Email: rohaizak@hotmail.com

Date of submission: 30 Dec, 2013

Date of acceptance: 11 Mar, 2014

### Introduction

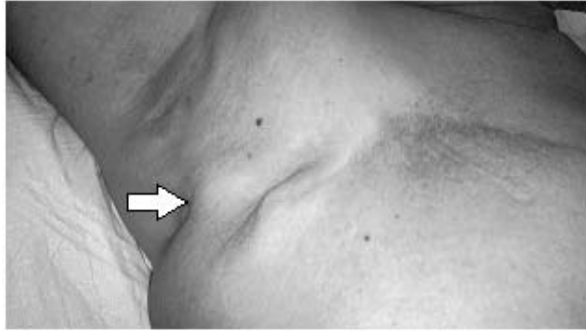
Radiation induced sarcoma is a late rare complication of radiotherapy. The cumulative incidence for radiation induced sarcoma has been reported to be 0.07% at 5 years, 0.27% at 10 years, and 0.48% at 15 years (1). Here in, we present an interesting case of radiation induced sarcoma diagnosed six years later, after completed radiotherapy treatment for breast carcinoma.

### Case Report

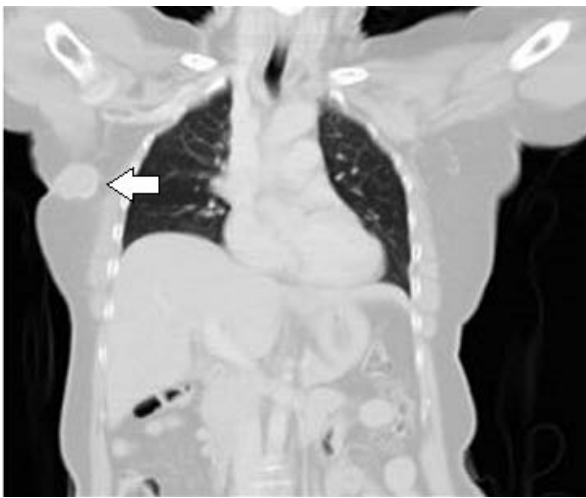A 58-year-old Chinese lady was diagnosed to have invasive ductal carcinoma of the right breast following a lumpectomy. She underwent mastectomy and axillary lymph node dissection. Histological sections of the breast tissue revealed tumour with free margins with no axillary lymph nodes metastases. The oestrogen and progesterone receptors were negative. There was no evidence of distant metastases. She underwent six cycles of chemotherapy consisting of cyclophosphamide, methotrexate and 5 fluorouracil. Subsequently, radiation therapy was given to the chest wall (at a dose of 40 Gray in 15 fractions).

After six years completion of primary treatment, she observed a lump progressively increasing in size in her right axilla. The lump was painless and did not limit the activity of the right upper limb. Clinical examination revealed a fixed hard mass on the right axillary region measuring 4 x 4cm overlying the previous axillary dissection scar (Fig. 1). Ultrasound investigation of the axilla showed a heterogenous lesion at the right axilla. Biopsy confirmed diagnosis of high grade sarcoma. Computed tomography of the thorax and axilla revealed a mass arising from the right axilla which was in close proximity with the latissimus dorsi. No nodules were seen in the lung and thorax (Fig. 2). Abdominal ultrasound showed no liver metastasis and isotope bone scan was normal.

Patient then underwent excision of the tumor and intra-operatively noted a hard mass at the right axilla measuring 5 x 5 x 4 cm. The mass infiltrated the latissimus dorsi. The tumor did not involve the long thoracic nerve or the thoracodorsal bundles. No enlarged axillary lymph node was detected. Patient was discharged well on second post operative day and planned for adjuvant chemotherapy and radiotherapy.



**Figure 1:** Fixed hard mass measuring 4x4cm at the previous axillary dissection scar with no evidence of chest wall recurrence. Contralateral breast and axilla were normal.

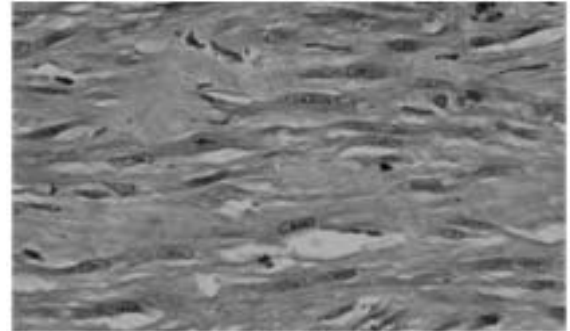


**Figure 2:** CT scan showed heterogenous lesion at the right axilla with no evidence of distant metastasis (arrow).

Histopathological examination confirmed the diagnosis of leiomyosarcoma (Fig. 3).

### Discussion

The role of adjuvant radiotherapy in post mastectomy patient is well established. It has been proven that radiotherapy prevents local recurrence in early breast cancer (2). Despite the benefit of the therapy, radiation therapy carries a low risk of sarcoma and the cumulative radiation incidence was 0.07%.at 5 years, 27% at 10 years, and 0.48% at 15 years (1). The criteria for diagnosis of radiation induced sarcoma was first described by Cahan et al (1998) (3). These criteria were: (a) previous history of radiotherapy, (b) asymptomatic history of latency period of at least 4 years, (c) sarcoma occurs at the previous irradiated site and (d) histological diagnosis. The latency period ranges between 2 to 50 years (1). Most reports of radiation induced sarcoma were related to radiation dose ranging between 60 to 80 Gy (1).



**Figure 3 :** Microscopically the tumor is composed of malignant spindle cells which are cigar shaped, hyperchromatic, moderately pleomorphic some with prominent nucleoli and vesicular chromatin. Pale eosinophilic fibrillary cytoplasm are noted which in areas show vacuolation. (H&E, original magnification x 60). Diagnosis of leiomyosarcoma was made after positive immunoreactivity towards vimentin, smooth muscle actin (SMA) and desmin.

The diagnosis of soft tissue sarcoma can be successfully made by tissue biopsy. The histological subtypes and grades can be determined for the vast majority of core needle biopsies. Pathologists who are experienced in examining soft tissue sarcoma can diagnosed it accurately in 95% to 99% of cases while comparing core needle with incisional biopsy diagnostic approaches (4). Interestingly, angiosarcoma has the highest reported incidence amongst all histological subtypes of radiation induced sarcoma following breast carcinoma treated by irradiation (5,6). Imaging features are not pathognomonic of radiation induced sarcoma (7). The current new radiodiagnostic imaging modalities of MRI and spiral CT might provide adequate information. Three-dimensional reconstruction CT enables excellent preoperative planning of the extent of the surgical resection and the need for reconstruction with plastic surgery, with the ultimate goal of achieving an R0 resection with low morbidity, e.g., primary wound healing (7,8).

Treatment for radiation induced sarcoma is wide surgical resection with immediate reconstruction. In order to obtain oncological clearance, surgeons must achieve at least 2cm microscopically clear margin (8). Chemotherapy and radiotherapy have shown non promising results, although doxorubicin and ifosfamide has shown modest potential improvement in survival (9). Current research focuses on molecular biology basis of the subtype-specific oncogene and protein products that could serve as treatment targets (10). Five-year survival rates has been reported to be 36% and the median survival after diagnosis of sarcoma is 34.2 months (1).

## Conclusion

The vast usage of radiotherapy as an adjunct in breast cancer management should be tailored to each patient. Although the incidence of radiation induced sarcoma is rare, but clinical suspicion should be considered especially in patients presenting with a mass following post radiotherapy treatment.

## References

1. Kirova YM, Vilcoq JR, Asselain B, Sastre-Garau X, Fourquet A. Radiation-induced sarcomas after radiotherapy for breast carcinoma a large-scale single-institution review. *Cancer* 2005; 104(4): 856-63.
2. Fisher B, Anderson S, Bryant J, et al. Twenty-year follow-up of a randomized trial comparing total mastectomy, lumpectomy, and lumpectomy plus irradiation for the treatment of invasive breast cancer. *N Engl J Med* 2002; 347: 1233-41.
3. Cahan WG, Woodward HQ, Higinbotham NL, Stewart FW, Coley BL. Sarcoma arising in irradiated bone: report of eleven cases. 1948. *Cancer* 1998; 82(1): 8-34.
4. Heslin MJ, Lewis JJ, Woodruff JM, Brennan MF. Core needle biopsy for diagnosis of extremity soft tissue sarcoma. *Ann Surg Oncol* 1997; 4(5): 425-31.
5. Yap J, Chuba PJ, Thomas R, et al. Sarcoma as a second malignancy after treatment for breast cancer. *Int J Radiat Oncol Biol Phys* 2002; 52(5): 1231-7.
6. Karlsson P, Holmberg E, Samuelsson A, Johansson KA, Wallgren A. Soft tissue sarcoma after treatment for breast cancer - a Swedish population-based study. *Eur J Cancer* 1998; 34(13): 2068-75.
7. Tang AP, Chu WC, Lam WW, Tse GM. Radiological appearance of post irradiation sarcoma of the chest wall after mastectomy. *Clin Imaging* 2005; 29(3): 185-8.
8. Thijssens KM, van Ginkel RJ, Suurmeijer AJ, et al. Radiation-induced sarcoma: a challenge for the surgeon. *Ann Surg Oncol* 2005; 12(3): 237-45.
9. Neuhaus SJ, Pinnock N, Giblin V, et al. Treatment and outcome of radiation-induced soft-tissue sarcomas at a specialist institution. *Eur J Surg Oncol* 2009; 35(6): 654-9.
10. Verweij J, Baker LH. Future treatment of soft tissue sarcomas will be driven by histological subtype and molecular aberrations. *Eur J Cancer* 2010; 46(5): 863-8.