

Case Report

Duodenal Duplication Cyst in an Adult: A Rare Case

Raghunath P (✉)¹, Neha K², Sakshi S¹, Rajgopal S¹, Kuladeepa AV³

¹Department of Surgery, Kasturba Medical College, Manipal University, Manipal, Udupi District, 576104 Karnataka, India.

²Department of Surgery, University Hospital North Staffordshire NHS Trust, City General, Newcastle Road, Stoke-on-Trent, ST4 6QG, United Kingdom.

³Department of Pathology, Srinivas Institute of Medical Sciences and Research centre, Srinivas Nagar, Mangalore District, 575021 Karnataka, India.

Abstract

Duodenal duplication cysts are rare congenital anomalies, found commonly in infants and children. In rare instances they can occur in adults, often manifesting clinically as pancreatitis. Here we present one such case of an 18-year-old female, who presented with symptoms of duodenal obstruction, weight loss and pancreatitis. She was diagnosed as having a duodenal duplication cyst (DDC) on a CT scan. She made a good recovery after a total cyst excision and this report aims to highlight the importance of clinicians having duplication cysts in their list of differential diagnoses as these cases are often under-diagnosed due to their rare occurrences.

Keywords: Duodenum, duplication cyst, adult, pancreatitis, vomiting, ERCP, surgery

Correspondence:

Dr Raghunath Prabhu, Department of Surgery, Kasturba Medical College, Manipal University, 576104 Manipal, India. Tel: +919448903817 Fax: 91-0820-2571927 Email: drraghu81@yahoo.co.in

Date of submission: 10 Jan, 2014

Date of acceptance: 1 Apr, 2014

Introduction

Intestinal duplication cysts are rare congenital anomalies (1) that occur at a frequency of 1:4500 (less than 30% diagnosed in adults) but are predominantly seen in white males (2). Even out of this figure, small intestinal duplication cysts are the most commonly seen, with other sites, such as, cervical esophageal, gastric, pyloric, duodenal, and rectal being comparatively rare. Duodenal duplication cysts (DDC) account for roughly 5% of all gastrointestinal duplications (3). The presentations are very vague and usually coincide with the size, type and location of the lesion, thereby manifesting in different ways. This makes it hard for a clinician to link non-specific abdominal symptoms to this condition. We report one such rare case of duodenal duplication cyst in an adult female who presented with a brief history of epigastric pain and intermittent vomiting. The diagnosis was confirmed by contrast enhanced computed tomography

scans and operative findings followed by histopathological analysis.

Case Report

An 18-year-old female was referred to our tertiary care university hospital in Southern India by a local hospital, following upper abdominal pain and intermittent vomiting for 15 days. She reported that the pain was insidious in onset and gradually progressive, mainly in the upper abdomen. It was associated with post-prandial vomiting, which was non-projectile and bilious in nature. There was no history of fever, diarrhea or constipation. There was loss of appetite and loss of weight over a short period. She had been otherwise fit and well with no previous operations. On examination, she was of thin build, conscious and oriented. There were no peripheral signs of any chronic disease. The abdomen showed no obvious mass but tenderness at the epigastric region during

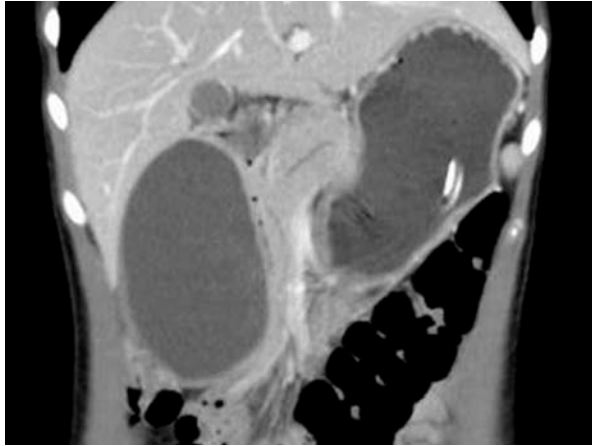

Figure 1: A contrast enhanced CT scan of the abdomen showing a well defined thin walled fluid filled cyst measuring 9.6 x 5.6 x 5.5 cm in the right sub-hepatic area.

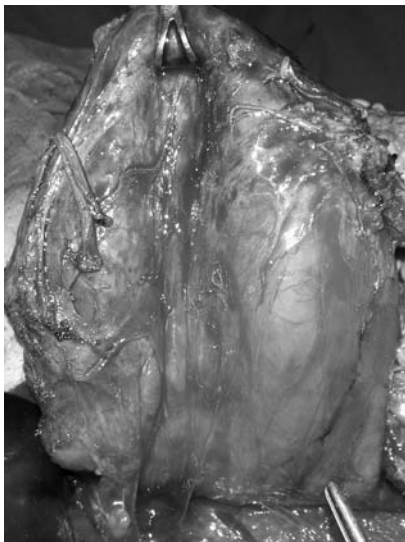

Figure 2: Intra-operatively a 10 x 5 cm cyst was found between the right lobe of liver and duodenum. The figure showing the specimen dissected all around and lifted up.

palpation. There was no guarding or rigidity. Per rectal examination was insignificant, along with all other systems. Serum Amylase was 532 U/L (normal range 30-110 U/L) and lipase 1084 U/L (normal range 5-208 U/L), suggesting pancreatitis. A contrast enhanced CT scan of the abdomen showed a well defined thin walled fluid filled cyst measuring 9.6 x 5.6 x 5.5 cm in the right sub-hepatic area (Fig 1). It was wedged between the 2nd part of the duodenum and right lobe of liver. There was no communication of the cyst with the duodenal lumen, although it was displacing and compressing the pylorus, 1st and 2nd parts of the duodenum medially and the gallbladder superiorly. The pancreas was normal in appearance. The features

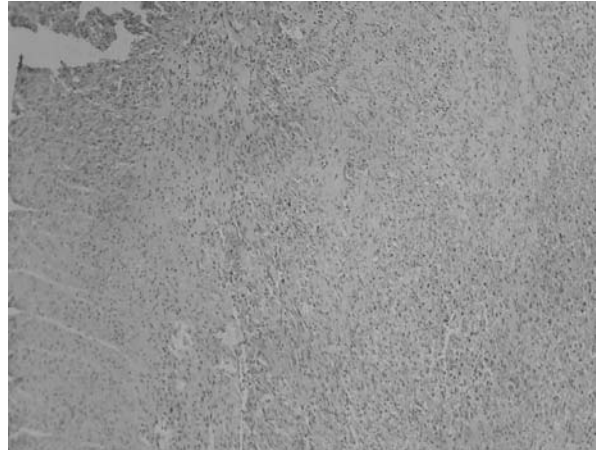


Figure 3: The histology sections showed intestinal mucosa with ischemic changes and transmural hemorrhagic infarction of bowel wall.

were suggestive of a DDC. She underwent a total cyst excision. Intra-operatively a 10 x 5 cm cyst was found between the right lobe of liver and duodenum (Fig 2). The cyst was aspirated and cyst wall excised. The histology sections showed intestinal mucosa with ischemic changes and transmural hemorrhagic infarction of bowel wall (Fig 3). The duodenal mucosa was intact. Post-operatively, she made an uneventful recovery.

Discussion

In 1937, Ladd formally defined duplication of the alimentary tract, consisting of 3 characteristics: a smooth muscle outline, a bowel epithelial lining and close attachment to the GI tract (4). Jejunal duplications are commonly encountered in clinical practice, followed by gastric and colonic ones. Interestingly, our patient had a duodenal duplication cyst, which is a very rare occurrence. DDC is a recognized rare cause of acute pancreatitis, usually encountered in the first two years of life (5). They are of unknown etiology but the widely accepted theory is that they occur as a result of aberrant luminal recanalization of the embryonic GI tract (6). About 15% of DDCs contain ectopic gastric mucosa (heterotopic mucosa), which can lead to ulcerations, perforations with peritonitis. Most patients present with different GI symptoms in early life with a minority remaining unsuspected till adulthood. A pancreatitis type picture can be due to two possible mechanisms: either a mobility-related duodenal obstruction of the major papilla outflow by the cyst, or the migration of biliary sludge and/or micro stones from the cyst to the biliary tree, similar to biliary pancreatitis. DDCs tend not to communicate with the

intestinal lumen. The most useful investigations of choice are ultrasonography and contrast enhanced CT scans (especially in DDCs, most useful in assessing mass effects and displacement of structures) (7). Endoscopic Retrograde Cholangio Pancreaticography, Percutaneous Transhepatic Cholangiography or Magnetic Retrograde Cholangio Pancreaticography can be useful in distinguishing a DDC from a choledochal cyst. In most cases surgery can be performed, although this depends on the location of a lesion and its proximity to adjacent structures. This can be particularly challenging in duodenal cysts whereby they can compromise the biliary and pancreatic ductal systems. In these cases drainage of the cyst into the duodenum or a Roux limb of the jejunum can also be done. Surgical resection is the treatment modality of choice for duodenal duplication cysts. A pancreaticoduodenectomy may sometimes be favoured due to the cysts' close proximity to the bilio-pancreatic duct. Laparoscopic approach offers a safe alternative to open surgery and is associated with improved outcome (8).

Conclusion

This was a rare case of adult duodenal duplication cyst presenting with vague abdominal symptoms, which highlights the importance of considering this rare congenital malformation as one of the differentials. Often duplications can be missed due to a patient's symptoms being classified as functional and investigations must therefore be made to look for evidence of duplications. The success of endoscopic procedures in some cases of duplications might help preoperative diagnosis and avoid surgery in certain cases, however, location of duodenal cysts dictate

management and therefore surgery is currently the best treatment modality.

References

1. Blake NS. Beak sign in duodenal duplication cysts. *Pediatr Radiol* 1984; 14(4): 232-3.
2. Polkowski M, Butruk E. Submucosal lesions. *Gastrointest Endosc Clin N Am* 2005; 15(1): 33-54.
3. Yang MC, Duh YC, Lai HS, Chen WJ, Chen CC, Hung WT. Alimentary tract duplications. *J Formos Med Assoc* 1996; 95(5): 406-9.
4. Stern LE, Warner BW. Gastrointestinal duplications. *Semin Pediatr Surg* 2000; 9(3): 135-40.
5. Seeliger B, Piardi T, Marzano E, Mutter D, Marescaux J, Pessaux P. Duodenal duplication cyst: a potentially malignant disease. *Ann Surg Oncol* 2012; 19(12): 3753-4.
6. Simstein NL. Congenital gastric anomalies. *Ann Surg* 1986; 52(5): 264-8.
7. Brown RL, Azizkhan RG. Gastrointestinal bleeding in infants and children: Meckel's diverticulum and intestinal duplication. *Semin Pediatr Surg* 1999; 8(4): 202-9.
8. Ballehaninna UK, Nguyen T, Burjonrappa SC. Laparoscopic resection of antenatally identified duodenal duplication cyst. *JLS* 2013; 17(3): 454-8.