

## Case Report

### Bilateral Unusual Variant of Sternalis Muscle

Simmi M (✉), Dalpat SC, Tuhin G

Department of Anatomy, Mahatama Gandhi Medical College and Associated Hospitals, Sitapura, Jaipur, Rajasthan, India.

#### Abstract

There is a need to record and discuss unusual anatomical variants with the advent of complex diagnostic and therapeutic tools as these variants could present a challenge to the radiologist or surgeon in arriving at a diagnosis. The sternalis muscle has been widely reviewed and studied since 17<sup>th</sup> century. It can be easily overlooked during breast surgery and may often cause diagnostic dilemma on mammography or CT scans. We hereby, report an unusual bilateral sternalis along with bilateral variations in pectoralis major muscles. Although sternalis has no known functional role, its presence has surgical implications during breast implant reconstruction surgery and in radiation therapy in breast carcinoma cases.

**Keywords:** Sternalis, pectoralis muscle, variations, breast, mammoplasty

#### Correspondence:

Dr Simmi Mehra, 403, Pearl Pride apts, 6-Vivekanand marg, C-scheme, Jaipur-302001, Rajasthan, India. Tel: +91-9929399941, Fax: +911412770677 Email: mehrasimmi61@yahoo.com

Date of submission: Feb 25, 2012

Date of acceptance: March 26, 2012

#### Introduction

The importance of continuing to record and discuss anatomical anomalies is imperative in the interventional methods of diagnosis and treatment. Sternalis muscle has been well described in the literature since 17<sup>th</sup> century (1). Incidence of the muscle varies according to sex, race and ethnicity (2). It is more common among women (8.7%) than men (6.4%) (3), 2.9-6.4% among Whites & 11% in Black races (4). Its reported incidence is 4-8% in Indians (5), 13.1% in Japanese, 3.3% in Filipinos and 1% in Chinese (4). It has been differently named by Anatomists as Parasternalis, Pectoris rectus or Pre-sternalis muscle (2). It is often bilateral and sometimes associated with variations of pectoralis major muscle (6,7). As described in standard textbooks (8) it is a fleshy band of longitudinal fibres of varying length and width, located close to and generally parallel to the sternum. It can arise from the sheath of rectus abdominis, aponeurosis of external oblique muscle, pectoralis major or costal cartilages

and ends above onto upper costal cartilages, manubrium or may be joined with sternal head of the sternocleidomastoid muscle. We hereby described an unusual presentation of this muscle, not described in literature so far.

#### Case Report

The sternalis muscle (Sm) was present bilaterally (Fig. 1), in an adult male cadaver, situated on either side of the sternum extending from the manubrium to the aponeurosis of external oblique (EO) muscle. Lowermost fibres of pectoralis major (Pm) muscle, on both sides, were observed to take origin from EO aponeurosis just near the origin of Sm and were separated by a triangular gap from the rest of the Pm muscle.

#### *Left Side*

The left Sm muscle was 17cm long and 2.2cm wide at its broadest part. It took origin as an aponeurotic band

5.2 cm from the median plane at the level of 5<sup>th</sup> intercostal space from EO aponeurosis just medial to the origin of lowest fibres of Pm muscle. The band then became fleshy and ascended over Pm muscle obliquely. The farthest distance of the Sm muscle from the median plane was 4cm at the level of 4<sup>th</sup> costal cartilage. At the sternal angle, it coursed medially towards manubrium and became aponeurotic (Fig.1A) over its surface. This 3cm long aponeurotic band was common for the left and right Sm muscles, and continued with the superficial sternal fibres of both the sternocleidomastoid (SCM) muscles (Fig.1B).

#### *Right Side*

The right Sm was 17cm long and 2cm wide at its broadest part. It took origin from EO aponeurosis similar to the left Sm, and lay furthest 3.8cm from the median plane at the level of 4<sup>th</sup> costal cartilage. Its upper end was aponeurotic and merged with the common aponeurotic band. At the level of sternal angle, part of Pm muscle took origin from the lateral part of Sm muscle (Fig. 2A).

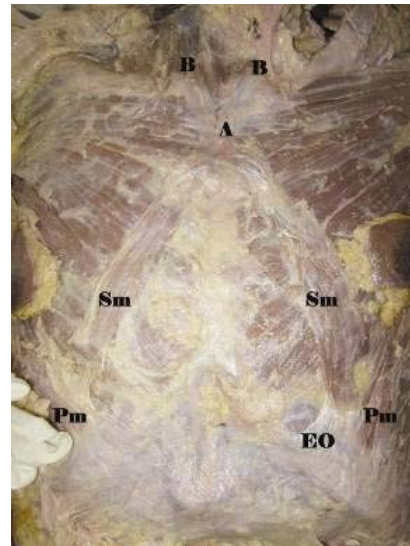
On division of the common aponeurotic band over the manubrium, we observed continuity between deeper sternal fibres of left SCM muscle (Fig. 2B) and right Pm muscle (Fig. 2C). Both the Sm muscles were innervated by the intercostal nerves.

#### **Discussion**

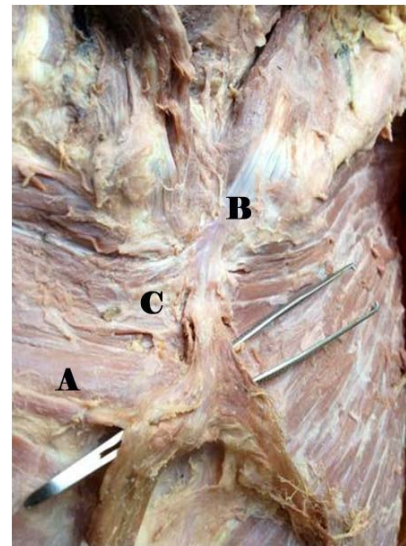
Literature on the sternalis muscle provides constantly varying assessments of the morphological presentation of this muscle, especially in its tendency to present bilaterally or unilaterally (9). Anomalies of sternalis in association with abnormalities of Pm muscle have been described (6,7,10,11).

Direct connection of muscle fibers between sternalis and Pm muscles has been reported (7) and in their case both sternales were continuous with respective SCM muscle, as observed in the present case. Both their sternales showed tendinous interconnections with thickenings of pectoral fascia near the lateral border of the respective Pm muscle at the level of 1<sup>st</sup> intercostal space whereas the right sternalis showed continuity with right Pm at the sternal angle.

Bilateral sternalis muscles were accompanied by unilateral absence of the sternal head of Pectoralis major muscle has been reported (10) thereby indicating a partial replacement of Pm muscle by sternalis. Three unilateral sternalis muscles and their continuity with



**Figure 1:** Sm-sternalis muscle; Pm- pectoralis major muscle; EO-aponeurosis of right external oblique muscle; A-common aponeurotic band of sternales; B- sternocleidomastoid muscle.



**Figure 2:** A-origin of part of right pectoralis major from right sternalis; B- deep fibres of left sternocleidomastoid muscle; C- continuity between left sternocleidomastoid and right pectoralis major muscles.

Pm muscle has been reported (11). Three sternales, one on right and two on the left, the left ones showing continuity with Pm muscle have been reported (12).

In the present case, we observed bilateral Sm muscles having a common aponeurotic upper end which was continuous with superficial fibers of both SCM muscles. The deep fibers of left SCM were seen to curve over manubrium and continue with right Pm muscle. Sternal fibres of right Pm muscle took origin

form the right sternalis at the level of sternal angle, thereby showing continuity between these muscles. Such connections between SCM, Pm and Sm muscles have not been observed so far.

An anatomical conundrum as is seen in our case should be noted by clinicians, surgeons, morphologists and radiologists. Knowledge of variants of sternalis can prevent them from overlooking or misinterpreting this unusual variant during diagnostic and surgical procedures. During routine mammography, sternalis may be visible as an irregular mass present medially giving rise to diagnostic confusion with carcinoma breast and should be excluded by CT or MR imaging (14). Oncologists suggest that detection of this muscle on mammography should be noted and conveyed to the Radiotherapist especially in breast cancer cases so that the target depth of radiation of internal mammary nodes can be adjusted if the muscle is spared during mastectomy. They recommend that a note stating the presence of sternalis must accompany the report for a follow up contralateral mammogram to facilitate the interpretation (15).

While this anatomic variant is rare, undoubtedly the busy reconstructive surgeon will encounter this muscle several times in his career. In augmentation mammoplasty performed in the submuscular plane, prostheses are commonly palpable or visible in the lower parasternal region of thin individuals. Presence of this muscle has been used to provide extra cover in these cases (16). A new technique using an elevated conjoint sternalis–pectoralis muscle flap has been devised for immediate implant reconstruction following mastectomy (17).

New muscular variations make it essential to document and report them especially when they mimic a pathology or be misinterpreted radiologically. Such complex intramuscular connections as is seen in our case should therefore be noted to prevent any iatrogenic injury or for eventual use in operative procedures.

## References

1. Loukas M, Bowers M, Hullett J. Sternalis muscles: A mystery still. *Folia Morphol* 2004; 63 (2): 147-149.
2. Arraez-Aybar LA, Sobrado-Perez J, Merida-Velasco JR. Left musculus sternalis. *Clin Anat* 2003; 16:350-354.
3. Scott–Conner CE, Al-Jurf AS. The sternalis muscle. *Clin Anat* 2002; 15: 67-69.
4. Jeng H, Su SJ. The sternalis muscle: An uncommon anatomical variant among Taiwanese. *J Anat* 1998; 193: 287-288.
5. Shah AC. The sternalis muscle. *Ind J Med Sci* 1968; 22: 46-47.
6. Kida MY, Kudoh H. Innervation of the sternalis muscle accompanied by congenital partial absence of the pectoralis major muscle. *Okajimas Folia Anat Jpn* 1991; 67: 449-455.
7. O’Neill MN, Folan-Curran J. Case report: Bilateral sternalis muscles with a bilateral pectoralis major anomaly. *J Anat* 1998; 193:289-292.
8. Williams SPL. *Gray’s Anatomy- The anatomical basis of medicine and surgery*. Edinburg: Churchill Livingstone, 1995, pp-838.
9. Jeleu L, Georgiev G, Surchev L. The sternalis muscle in the Bulgarian population: Classification of sternales. *J Anat* 2001; 199: 359-363.
10. Kumar H, Rath G, Sharma M, Kohli M, Rani B. Bilateral sternalis with unusual left sided presentation: A clinical perspective. *Yonsei Med J* 2003; 44(4): 719-722.
11. Ramachandran K, Kothandaraman U. Three unilateral recti sternalis muscles – an unusual variation and its clinical significance. *Eur J Anat* 2010; 14(1): 99-103.
12. Sarikcioglu L, Demirel BM, Oguz N, Ucar Y. Three sternalis muscles associated with abnormal attachments of the pectoralis major muscle. *Int J Exp Clin Anat* 2008, 2: 67-71.
13. Bradley FM, Hoover HC Jr, Hulka CA et al. The sternalis muscle: An unusual normal finding seen on mammography. *Am J Roentgen* 1996; 166: 33-36.
14. Nuthakki S, Gross M, Fessell D. Sonography and Helical computed tomography of the sternalis muscle. *J Ultrasound Med* 2007; 26: 247-250.

15. Harish K, Gopinath KS. Sternalis muscle: Importance in surgery of the breast. *Surg Radiol Anat* 2003; 25: 311-314.
16. Khan UD. Use of the Rectus sternalis in augmentation mammoplasty: Case report and literature search. *Aesth Plast Surg* 2008; 32:21-24.
17. Schulman MR, Chun JK. The conjoined sternalis-pectoralis muscle flap in immediate tissue expander reconstruction after mastectomy. *Ann Plast Surg* 2005; 55(6): 672-675.